

Facial treatment with acoustic wave therapy for improvement of facial skin texture, pores and wrinkles

Maurice A. Adatto MD  | Robyn M. Adatto-Neilson RN

Skinpulse Dermatology and Laser Centre,
Geneva, Switzerland

Correspondence

Maurice Adatto, Skinpulse Dermatology and
Laser Centre, Geneva, Switzerland.
Email: madatto@skinpulse.ch

Abstract

Background: A frequent demand among the female and male population is the reduction of facial wrinkles and pores, and additionally, the improvement of the facial skin texture preferentially achieved by noninvasive treatments.

Aims: The objective of this study was to demonstrate the efficacy and safety of acoustic wave therapy (AWT) and extracorporeal pulse activation therapy (EPAT) technology using mechanical waves in the treatment of facial skin.

Methods: Treatment was performed on the face of 12 patients, with the D-ACTOR 200 (Storz Medical AG) using radial acoustic wave technology, EPAT. Within 6 weeks, six acoustic wave treatment sessions have been performed. A follow-up visit was performed 6 weeks after the last treatment.

Results: Measurements with the 3D camera system clearly and objectively demonstrate a significant diminution in facial wrinkles and pores. Additionally, an improvement in skin texture was recognized.

Conclusions: This study, although performed on a small number of patients, tends to show the safety and efficacy of radial AWT in treating facial wrinkles, skin texture, and pores and in a noninvasive way.

KEYWORDS

acoustic wave therapy, facial skin, skin texture, pore size, wrinkles

1 | INTRODUCTION

1.1 | Formation of facial pores and wrinkles, and deterioration of the skin texture

Reduction of pores and wrinkles by noninvasive means is a frequent request among the male and female population. Many people suffer from poor skin texture caused by the combination of too high sun exposition and age. The reason for aging of skin is the reduction of elastin, collagen, protein and hyaluronic acid. The skin during the aging process is less supplied with blood, because the efficacy of the blood vessels in the dermis layer is reduced. The dermis, which is normally supplying the epidermis with nutrition, cannot sufficiently maintain its functionality. The circulation of oxygen and nutrition is therefore reduced, and the regeneration of cells is decelerated. Due to this reduced

supply, the skin loses its shiny appearance. Skin aging, especially on the face, also induces a loss of elasticity and skin texture changes, for example, pore size enlargement. Due to the reduction of collagen, the skin is less even and tight, and connective tissue becomes more flaccid.

1.2 | Acoustic wave therapy—AWT and EPAT

Acoustic wave therapy is a noninvasive technique using mechanical stimulation by acoustic waves.^{1,2} They have been developed from focused shockwave technology originally used in lithotripsy for decades for urologic stone disintegration. In the validation of the side effects of this destructive treatment, the healing effect of shock waves in cases of nonunion of bone fractures was first detected by Valchanou and Michailov.³ After the detection of the positive healing

effect of this treatment, shock waves were used in the treatment of different orthopedic disorders during the last decades. Shock waves have proven to be effective, not only for tendon and muscle pain reduction, but also for the dissolution of shoulder calcifications and for nonhealing wounds. Furthermore, acoustic waves were successfully used in the treatment of cellulite⁴⁻⁸ to improve the skin appearance. The benefits of body shaping of this technology are to reduce the fat layer, for example, on the thighs and buttocks.⁹

On behalf of their lower energy, acoustic waves have a stimulating effect on tissue. One can distinguish between focused and radial acoustic waves. EPAT is often used to describe the pneumatically generated radial acoustic waves. They have typically higher energy per pulse, compared to the focused acoustic wave lower energy flux density, but typically higher energy per pulse. EPAT relies on long-term positive experience and on reports in the scientific literature confirming the effectiveness of acoustic wave therapy.

1.3 | Biological effects on skin and improvement of skin elasticity

According to Wang,¹⁰ shock waves trigger a cascade of effects, which begins with the application of physical energy in the form of acoustic waves. Ultimately, these waves lead to the release of eNO and a number of growth factors (VEGF, BMP, TGF, etc) resulting in tissue regeneration based on improved metabolic activity, the formation of new vessels, bone and collagen and stimulation of stem cells. These effects are accompanied by healing processes that are still a topic of scientific investigations thus far, but that leads to successful therapy in the treatment of a number of indications including cardiologic disorders, such as angina pectoris¹¹ or Peyronie's disease.¹²

The acoustic waves have an effect on the increase in cell wall permeability and result in an increased release of triglycerides⁴ and regeneration of connective tissue.⁵ In vitro tests have shown that the application of acoustic pulses leads to increased short-term cell permeability that allows distinct active substances (eg, cytostatic agents) to be transferred to or from (eg, triglycerides) the cells.^{5,13} Moreover, acoustic waves lead to an increased collagen production. Christ et al⁴ have shown in their study on behalf of ultrasound images the obvious changes in tissue structure. It was observed that the network of collagen/elastic fibers in the dermis and subcutis becomes denser and measurably firmer.

The observations and results of these studies are confirming the positive effects on biologic tissue, such as the stimulation of microcirculation and the improvement in cell permeability.^{13,14}

1.4 | Acoustic wave effects on skin

Skin aging gradually weakens the skin's natural defense mechanisms. Because of the influence of oxygen radicals, protein molecules increasingly accumulate in the skin. However, free radicals are not only produced in response to external stimuli, such as sunlight or ozone,

but also accumulate in the tissue as a result of other factors such as smoking, stress, an unhealthy diet, or excess weight.

Another factor to be considered is the blood circulation in the skin, which determines the transport of oxygen and nutrients and the migration of immune cells.⁶ Intrinsic movements of the smallest terminal vessels in the microvascular system are an elementary characteristic of micro angiodynamics and allow the blood flow through the vascular bed to be regulated. An accelerated blood flow and high vasomotor activity stimulate the metabolism. The release of nitric oxide stimulates vasodilatation, neovascularization, and growth factor release.

In previous studies, the beneficial effect on skin appearance and elasticity was evaluated and demonstrated.⁴⁻⁸ The objective of these studies was to demonstrate the efficacy and safety of AWT/EPAT in the management of cellulite, skin appearance, and body shaping. A controlled, randomized study evaluated the effects of treating cellulite with acoustic waves.⁸ The skin elasticity results showed an obvious positive improvement after the treatment. The improvement in the skin elasticity value was statistically significant.

Based on this experience, we hypothesized that the same technology could improve signs of aging on the face, such as pores and wrinkles, and improve the overall skin texture. Additionally, with this treatment patients only feel a vibrating sensation. A redness of the treated skin due to the increased blood circulation is typically seen only short after the treatment.

The objective of this study is to demonstrate the efficacy and safety of AWT using extracorporeal pulse activation technology (EPAT) for facial signs of aging.

2 | MATERIALS AND METHODS

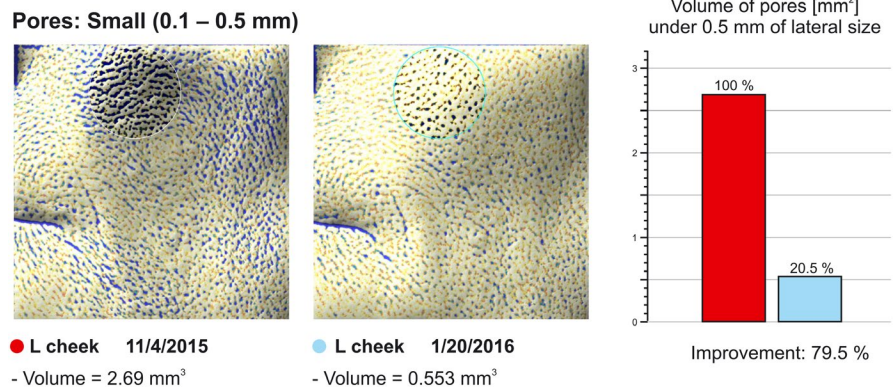
This study followed the principles of the declaration of Helsinki. All mandatory laboratory health and safety procedures have been complied within the course of conducting the study. The treatment was performed with the D-ACTOR 200 using extracorporeal pulse activation technology, EPAT. The D-ACTOR handpiece was used for the application of acoustic waves. The D-ACTOR handpiece is a high-frequency vibrating system (100-100 kHz) operated by compressed air generating "high impact" acoustic radial waves, which stimulate the target tissue and activate the blood and lymphatic flow. The transmitter used was the F15 tip, which concentrates the acoustic waves in a small area directly under the surface in the epidermis and dermis, in order to improve the energy transmission and to allow smooth gliding over the skin surface ultrasound coupling gel that has been used.

Twelve patients were treated with acoustic wave therapy during this study. All patients gave their written informed consent. All patients had no parallel treatments, that is, peelings, injections, or topicals. The mean age was 52.5 years.

All patients received six treatments in six weeks, at one-week intervals. During one session, 10.000 pulses were applied to each side of the face. The energy level was adjusted at a low level of 1.2-1.8 bar.

Pictures were taken with a 3D camera before the treatments and six weeks after the last treatment to compare skin texture

FIGURE 1 The value of “volume of pores” decreased from 2.69 mm³ before the treatment (B) to 0.55 mm³ at the follow-up, 6 weeks after the treatment



roughness, pore size, and depth of wrinkles. Standard 2D pictures were also taken with a specialized digital camera. All patients provided a self-assessment with a questionnaire.

The study outcome is documented by the following parameters collected prior to the treatment and at the follow-up, 6 weeks after the last treatment:

- 2D digital picture of the treated areas (Profect Full Body System; Profect Medical Technologies LLC).
- 3D camera pictures (Antera 3D System; Miravex)
- Patient satisfaction questionnaire

No anesthesia was needed as the procedure is almost painless. No sun protection was required as it is not a light-based treatment. Patients have only a vibrating sensation. A redness of the treated skin is typically seen, at maximum a couple of hours after the session.

3 | RESULTS

3.1 | Measurements with 3D camera

The camera system clearly demonstrates a decrease in skin roughness, pores, and wrinkles. All patients showed measurable and significant results with the 3D Miravex Antera 3D camera. An example

of the before and follow-up scan with the reduction of the pores is shown in Figure 2.

Measurements with the 3D measurement system clearly demonstrate a significant decrease in skin roughness, volume of pores, and wrinkles.

Statistical evaluation was performed with the software XLSTAT 2018.4 and Wilcoxon and Mann-Whitney calculator.¹⁵ The results are summarized in Table 1. The Kolmogorov-Smirnov test results in non-normal distribution of the collected data, and thus, the *Wilcoxon signed-rank and Mann-Whitney tests* were performed evaluating the values collected at baseline (B) and at follow-up (FU) after 6 weeks. The *P*-value for the three evaluated parameters is presented.

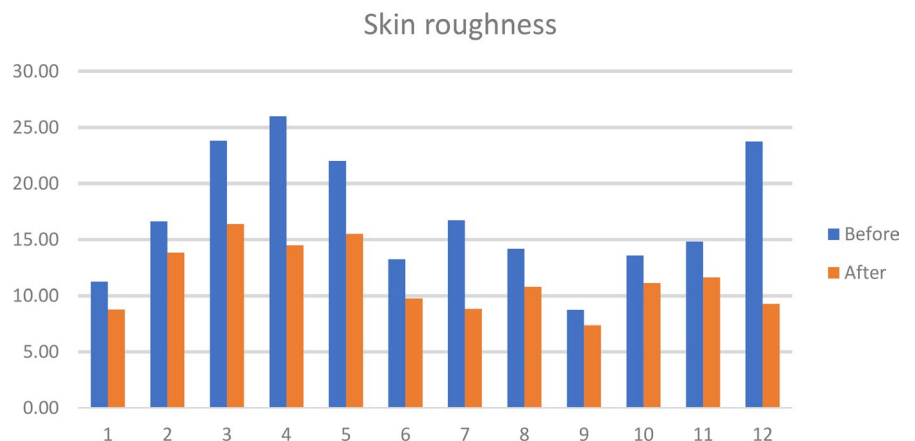
3.2 | Measurement of skin roughness

Skin roughness was measured from 0.1 to 1 mm. For skin roughness, there is a statistically significant difference from baseline 17.6 mm³ to follow-up 11.48 mm³ and accordingly a total reduction of 5.58 mm³.

3.3 | Measurement of pores

Pores of the facial skin were evaluated with the volume of small depressions of 0.1-0.5 mm. Measurements with the 3D camera

FIGURE 2 Skin roughness of patient 1-12. Before treatment and at follow-up, 6 weeks after the last treatment



Volume of pores

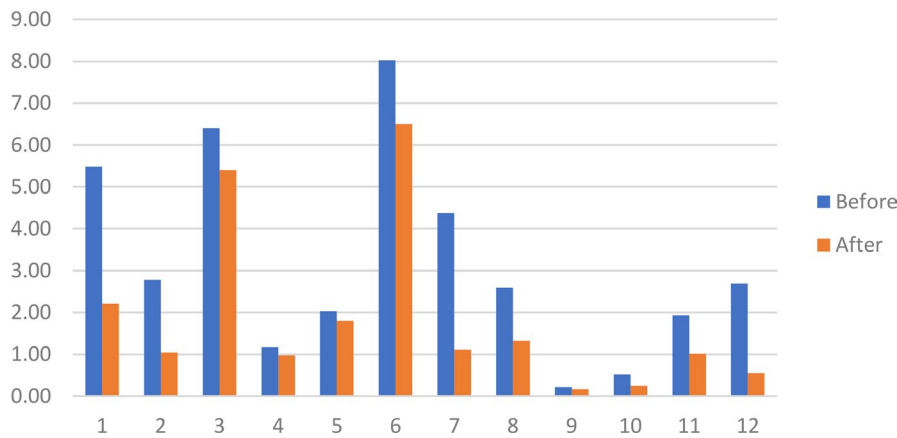


FIGURE 3 Volume of pores of patient 1-12. Before treatment and at follow-up, 6 weeks after the last treatment

TABLE 1 Statistical evaluation of skin roughness, pore size and wrinkles at baseline and at FU after 6 weeks

	Before (average value), B	After (average value), FU
Skin roughness	17.06	11.48
Significance	$P = .006$	
Pores	3.18	1.86
Significance	$P = .044$	
Wrinkles	0.11	0.07
Significance	$P = .029$	

system clearly demonstrate a significant decrease in the averaged volume of pores from 3.18 mm before treatment to 1.86 mm at the follow-up.

3.4 | Measurement of wrinkles

Wrinkle depths were measured between 0.1 and 1 mm. The averaged wrinkles' deepness decreased slightly from 0.11 to 0.07 mm at the follow-up measurement. The 3D camera system clearly demonstrates a significant decrease in wrinkle depth, see Table 1.

All patients felt a difference by touching their skin. Patients also recognized an improvement in skin texture, firmness, and tightness. Some patients noticed a difference as a more defined jawline.

No patient had side effects or problems after the treatments. Some patients experienced a little skin redness, which disappeared within 2 hours. All patients would recommend the treatment. The authors confirm that the data supporting the findings of this study are available within the article.

3.5 | Measurements with 2D camera

The pictures with the conventional digital camera did not show quantitative differences. Therefore, no evaluation or analysis was performed (Figure 1-3).

4 | DISCUSSION

This is the first study with objective measurements for the treatment of facial skin with AWT. In spite of the small number of patients evaluated, there is a significant level of improvement as documented by quantitative and qualitative measurements.

The measurement with 2D pictures is not an adequate tool to quantify the improvement of this treatment.

There were no side effects observed except some minor pain for a few patients during therapy and slight skin reddening afterward, lasting for a couple of hours. The minor and temporary side effects also confirm the safety of AWT and EPAT.

The purpose of this study was to investigate the safety and efficacy of AWT in treating the facial skin under standardized treatment and follow-up conditions. Patients clearly benefit from a reduction in the appearance of wrinkles, pores, and skin texture at the follow-up, 6 weeks after the last treatment. AWT® not only provides a reduction of wrinkles and roughness but also a skin texture improvement.

This study, although performed on a small number of patients, tends to show the safety and efficacy of AWT in treating facial skin texture, pores, and wrinkles. AWT and EPAT for facial treatments are a safe and effective method for reducing signs of skin aging on the face.

ORCID

Maurice A. Adatto  <https://orcid.org/0000-0003-1428-4174>

REFERENCES

1. Novak P. Physics: F-SW and R-SW: shockwave in praxis: multidisciplinary medical applications. Level 10 Verlag. 2014;28-49.
2. Wess O. Physikalische Grundlagen der extrakorporalen Stosswellentherapie. *J Mineralstoffwechsel*. 2004;11:7-18.
3. Valchanou VD, Michailov P. High energy shock waves in the treatment of delayed and nonunion of fractures. *Int Orthop*. 1991;15:181-184.
4. Christ C, Brenke R, Sattler G, Siems W, Novak P, Daser A. Improvement in skin elasticity in the treatment of cellulite and

- connective tissue weakness by means of extracorporeal pulse activation therapy. *Aesthetic Surg J*. 2008;28(5):538-544.
5. Siems W, Grune T, Voss P, Brenke R. Anti-fibrosclerotic effects of shock wave therapy in lipedema and cellulite. *BioFactors*. 2005;24(1-4):275-282.
 6. Angehrn F, Kuhn C, Voss A. Can cellulite be treated with low-energy extracorporeal shock wave therapy? *Clin Interv Aging*. 2007;2(4):623-630.
 7. Smalls LK, Lee CY, Whitestone J, Kitzmiller WJ, Wickett RR, Visscher MO. Quantitative model of cellulite: three-dimensional skin surface topography, biophysical characterization and relationship to human perception. *J Cosmet Sci*. 2005;56(2):105-120.
 8. Adatto M, Adatto-Neilson R, Servant JJ, Vester J, Novak P, Krotz A. Controlled, randomized study evaluating the effects of treating cellulite with AWT®/EPAT®. *J Cosmet Laser Ther*. 2010;12:176-182.
 9. Adatto M, Adatto-Neilson R, Novak P, Krotz A, Haller G. Body shaping with acoustic wave therapy AWT®/EPAT®: randomized, controlled study on 14 subjects. *J Cosmet Laser*. 2011;13:291-296.
 10. Wang CJ. An overview of shock wave therapy in musculoskeletal disorders. *Chang Gung Med J*. 2003;26:22-232.
 11. Gutersohn A, Caspari G, Erbel R. Autoangiogenesis induced by cardiac shock wave therapy (CSWT) increases perfusion and exercise tolerance in endstage CAD patients with refractory angina. *Circ J*. 2005;69(Suppl 1):379.
 12. Abdel-Salem Y, Budair Z, Renner C, et al. Treatment of peyronie's disease by extracorporeal shockwave therapy: evaluation of our preliminary results. *J Endourol*. 1999;13:549-552.
 13. Delius M, Ueberle F, Guo L. Anwendung von Stosswellen für den Transfer von Molekülen in Zellen. *Biomed Tech (Berl)*. 2002;47(s1a):382-385.
 14. Braun M, Worblewska K, Daser A. Effekte der Stosswellentherapie bei pathologischen Veränderungen des subkutanen Fettgewebes. *Aesthetische Dermatologie*: MDM Verlag. 2005:11-17.
 15. Marx A, Backes C, Meese E, Lenhof HP, Keller A. EDISON-WMW: exact dynamic programming solution of the Wilcoxon-Mann-Whitney test. *Genomics Proteomics Bioinformatics*. 2016;14(1):55-61.

How to cite this article: Adatto MA, Adatto-Neilson RM. Facial treatment with acoustic wave therapy for improvement of facial skin texture, pores and wrinkles. *J Cosmet Dermatol*. 2020;00:1-5. <https://doi.org/10.1111/jocd.13327>