

CASE REPORT AND SHORT REPORT

Extracorporeal shock wave treatment of capsular fibrosis after mammary augmentation – Preliminary results

NORBERT HEINE¹, LUKAS PRANTL² & MARITA EISENMANN-KLEIN¹

¹Caritas-Krankenhaus St. Josef, Klinik für Plastische und Ästhetische, Hand- und Wiederherstellungs-Chirurgie, Regensburg, Germany and ²Universitätsklinikum Regensburg, Funktionsbereich Plastische- Hand- und Wiederherstellungschirurgie, Regensburg, Germany

Abstract

Extracorporeal shock wave therapy has undergone continuous development and has become a well-established therapy option both in urology and in orthopaedics/trauma surgery. Experimental and clinical studies have proved the effectiveness of extracorporeal shock wave therapy in the treatment of connective tissue diseases such as fibromatosis.

The pathomechanism of capsular fibrosis after augmentation of the female breast with silicone implants presents a series of analogies with mechanisms that are generally recognised to be associated with fibroproliferative diseases. The starting point of the disease is the inflammatory reaction caused by the silicone and/or by the sub-clinical bacterial contamination of the implant surface and can create an inflammatory reaction and fibrosis.

A total of 19 cases of capsular fibrosis in 12 patients following insertion of mammary implants were treated with extracorporeal shock wave therapy. The therapy was performed with the Duolith SD1 system manufactured by Storz Medical. Shock waves were applied with the C-Actor handpiece designed for planar shock waves.

Extracorporeal shock wave therapy appears to be a non-invasive, well-tolerated and easy-to-use procedure for pain reduction and fibrotic tissue softening, especially after aesthetic breast implant augmentation.

Key Words: breast augmentation, connective tissue, extracorporeal shock wave therapy, mammary implants

Introduction

Since its introduction in 1980, extracorporeal shock wave therapy has undergone continuous development and has become a well-established therapy option both in urology and in orthopaedics/trauma surgery. In addition to its effectiveness in urolithotripsy applications (ESWL), ESWT has shown to provide successful results in the treatment of pseudarthrosis, joint disorders, epicondylitis (1,2), connective tissue diseases such as Dupuytren's contracture and Ledderhose's syndrome, leg ulcer and other conditions. Experimental and clinical studies have proved the effectiveness of extracorporeal shock wave therapy in the treatment of connective tissue diseases such as fibromatosis (3). The inflammatory cytokines interleukin-I and interleukin-VI have been shown to diminish.

The pathomechanism of capsular fibrosis after augmentation of the female breast with silicone

implants presents a series of analogies with mechanisms that are generally recognised to be associated with fibroproliferative diseases (4). The starting point of the disease is the inflammatory reaction caused by the silicone and/or by the sub-clinical bacterial contamination of the implant surface (5). This results in a proliferation of inflammatory cells, primarily T-lymphocytes and macrophages with increased production of profibrotic cytokines such as IL-13, TGF- β and others (6). These inflammatory cells stimulate fibroblasts which transform into myofibroblasts expressing SMA. Fibroblasts and myofibroblasts increasingly produce extracellular matrix and thus cause capsular thickening and contracture (7–9). Contrary to the clinical grading of capsular fibrosis defined by Baker (10), the histological classification of the disorder according to Wilflingseder (11) also considers the degree of progression of the inflammatory reaction and fibrosis.

Materials and methods

In the period between September 2008 and December 2009, a total of 19 cases of capsular fibrosis in 12 patients following insertion of mammary implants were treated with extracorporeal shock wave therapy at our clinic. Patients were aged between 24 and 67 years (average age 46 years). Among the 12 females treated with shock waves, five subjects suffered from unilateral capsular fibrosis, while seven patients had bilateral contracture.

Implants for breast reconstruction had been inserted in seven cases (five females); three out of these five patients had received a permanent unilateral expander prosthesis type Becker 35 (manufactured by Mentor). In four cases (2 females), permanent round implants had been used for bilateral reconstruction. In 12 cases (seven patients), implant augmentation had been performed with an aesthetic indication. In 11 out of these 12 cases, smooth round implants had been inserted. In the remaining case, no information was available as to the type of implant used. The implant volume was between 150 and 325 ml for round implants, and between 195 and 460 ml for expander prostheses.

The therapy was performed with the Duolith SD1 system manufactured by Storz Medical. Shock waves were applied with the C-Actor handpiece (Figure 1) which is designed for planar shock waves. Owing to its superficial pulse emission, this handpiece is ideal for the targeted application of shock waves to the subcutaneous capsular fibrosis without causing damage to deeper structures. The therapy system is designed for a maximum dynamic energy range of 0.38 mJ/mm² (26 MPa).

Each patient received between 3 and 26 shock wave therapy sessions (average number of sessions: 8) between 2 and 92 months after the surgery (average: 27 months). In general, treatment was performed at weekly intervals. The average overall duration of the shock wave therapy was 13 weeks (3–40 weeks). Ten patients received 1,000 shock waves per therapy

session, while one subject was treated with 1,500 shock waves per treatment. In one patient, the number of shock waves was increased from 1,000 to 1,500 in the course of the therapy. The selected shock wave intensity was between 0.22 and 0.38 mJ/mm². In each session, the therapy effect on the severity of capsular fibrosis (Baker grades), subjective pain and experienced side effects were assessed by partly standardised questioning of the patients.

Results

Out of the 12 patients treated, five subjects had developed capsular fibrosis after breast reconstruction.

In three out of these five patients, a permanent expander prosthesis type Becker 35 (manufactured by Mentor) had been inserted. These three subjects were treated with an average of seven extracorporeal shock wave therapy sessions (minimum five sessions, maximum nine sessions). None of these patients reported any alleviation of pain or reduction in the hardening after the shock wave treatment. One patient underwent implant replacement three months after completion of the therapy.

The other two patients had received bilateral breast reconstruction with smooth round implants after mastectomy. One of these patients underwent shock wave therapy of both implants, whereas the second subject had only one implant treated. These two patients received three and five shock wave therapy sessions respectively. Treatment was performed 54 and 14 months after reconstructive implantation respectively. Again, none of the two subjects reported any alleviation of pain as a result of shock wave therapy.

A total of seven patients had received breast augmentation with an aesthetic indication or to correct a congenital malformation. In another patient, the healthy breast had been corrected for aesthetic reasons to match it to the reconstructed breast after placement of an expander prosthesis.

In six of the aforementioned seven patients, round and smooth implants had been inserted for aesthetic breast augmentation. One subject had received a unilateral implant of unknown type to correct breast asymmetry. The patient in the reconstruction group had undergone augmentation of the healthy breast to improve symmetry after expander reconstruction of the other breast. In this patient, shock wave therapy was performed on both implants.

Three of these patients had received bilateral primary aesthetic augmentation with smooth implants with a volume of 200–240 ml. One patient had undergone unilateral surgery to correct breast asymmetry, while another patient with tuberous breast malformation had received bilateral surgery. In one subject, re-augmentation with smooth implants had been necessary following an infection, while another patient had previously undergone two implant replacements due to the development of capsular



Figure 1. C-Actor handpiece of the Duolith SD1 system.

fibrosis. As described above, one patient had received augmentation of the healthy breast to improve symmetry after expander reconstruction of the other breast.

Among the three subjects having undergone primary aesthetic augmentation, one patient reported that pain and breast hardening had significantly diminished after 26 shock wave therapy sessions. One patient reported that after four sessions the tension on one side had improved while the hardening had remained unchanged.

As far as the patients with breast malformation were concerned, one patient who had received breast augmentation to improve symmetry reported that pain had significantly diminished in the course of six shock wave therapy sessions, while one patient with tuberous breast malformation reported to have experienced a slight reduction in capsular hardening and that the degree of improvement varied between the two sides. The patient having undergone re-augmentation following an infection reported an improvement in capsular hardening and diminishing tension pain after 12 shock wave sessions. One patient who had undergone three implant replacements due to the development of capsular fibrosis reported an improvement in capsular pain after eight therapy sessions.

The only complication associated with the shock wave therapy was slight skin reddening lasting for several hours, which was observed in one case, caused by the gel applied to the skin for shock wave application. None of the patients treated reported any deterioration of pain.

Discussion

The number of study reports dealing with the modulating and partly positive effect of extracorporeal shock wave therapy on chronic inflammatory and fibroproliferative diseases in the field of orthopaedics/trauma surgery has continuously increased during the last few years. The use of this procedure in the treatment of severe capsular fibrosis (Baker Grades III, IV) after breast reconstruction or augmentation with silicone implants is based on a similar indication because, similar to the aforementioned disorders, an inflammatory reaction inducing a connective tissue fibrosis is assumed to be the primary cause of the capsular contracture.

The initial results of our descriptive cross-sectional study confirm positive results in about 53% (10 out of 19) of the capsular fibrosis cases treated with shock waves. Patients who had undergone breast reconstruction after mastectomy did not experience any significant improvement of pain. Contrary to these findings, a moderate to marked alleviation of pain was reported by all but one of the patients who had received breast augmentation with an aesthetic

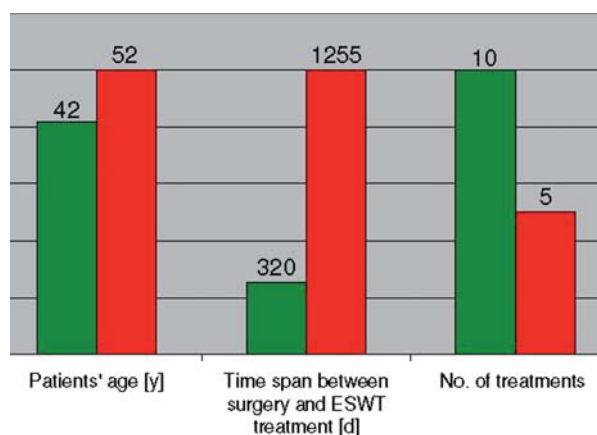


Figure 2. Comparison of various, treatment related parameters of capsular fibrosis patients with successful (green) and unsuccessful (red) outcome of ESWT treatment.

indication (success rate 83%). None of the patients reported any deterioration of pain or significant side effects caused by the shock wave therapy.

Despite the large parameters spread in this study, interesting trends can be derived from the results obtained which should be investigated in further research. In the group with successful ESWT treatment there were only patients with aesthetic augmentation (Figure 2), but, when considering other treatment-related parameters, another relationships immerse: patients with positive outcome were on an average 10 years younger than the patients in the unsuccessful group, the time span between augmentation surgery and the start of ESWT was only about 1 year as opposed to about 3.5 years in the unsuccessful group and the number of therapy sessions performed was significantly higher (10 vs 5) for the successfully treated patients.

In conclusion, it can be said that extracorporeal shock wave therapy appears to be a non-invasive, well-tolerated and easy-to-use procedure for pain reduction and fibrotic tissue softening, especially after aesthetic breast implant augmentation. ESWT seems to provide satisfactory therapy results in patients who would otherwise have to undergo surgical revision with implant replacement or autogenous flaps.

Declaration of interest: The authors of the manuscript are technically assisted by Storz Medical AG. Dr. Heine received financial publication support from Storz.

References

1. Metzner G, Dohnalek C, Aigner E. High-energy Extracorporeal Shock-Wave Therapy (ESWT) for the treatment of chronic plantar fasciitis. *Foot Ankle Int.* 2010;31:790–796.
2. Storheim K, Gjersing L, Bølstad K, Risberg MA. Extracorporeal shock wave therapy (ESWT) and Radial extracorporeal shock wave therapy (rESWT) in chronic musculoskeletal pain. *Tidsskr Nor Laegeforen.* 2010;130:2360–2364.

3. Hausdorf J, Sievers B, Schmitt-Sody M, Jansson V, Maier M, Mayer-Wagner S. Stimulation of bone growth factor synthesis in human osteoblasts and fibroblasts after extracorporeal shock wave application. *Arch Orthop Trauma Surg.* 2011;131:303–309. Epub 2010 Aug 22.
4. Wynn TA. Review. Common and unique mechanisms regulate fibrosis in various fibroproliferative diseases. *J Clin Invest.* 2007;117:524–529.
5. Poepl N, Schreml S, Lichtenegger F, Lenich A, Eisenmann-Klein M, Prantl L. Does the surface structure of implants have an impact on the formation of a capsular contracture? *Aesthetic Plast Surg.* 2007;31:133–139.
6. Prantl L, Pöpl N, Horvat N, Heine N, Eisenmann-Klein M. Serologic and histologic findings in patients with capsular contracture after breast augmentation with smooth silicone gel implants: is serum hyaluronan a potential predictor? *Aesthetic Plast Surg.* 2005;29:510–518
7. Hedén P, Bronz G, Elberg JJ, Deraemaeker R, Murphy DK, Slicton A, et al. Long-term safety and effectiveness of style 410 highly cohesive silicone breast implants. *Aesthetic Plast Surg.* 2009;33:430–436;discussion 437–8. Epub 2009 May 13.
8. Wong CH, Samuel M, Tan BK, Song C. Capsular contracture in subglandular breast augmentation with textured versus smooth breast implants: a systematic review. *Plast Reconstr Surg.* 2006;118:1224–1236.
9. Schreml S, Heine N, Eisenmann-Klein M, Prantl L. Bacterial colonization is of major relevance for high-grade capsular contracture after augmentation mammoplasty. *Ann Plast Surg.* 2007;59:126–130.
10. Spear SL, Baker JL Jr. Classification of capsular contracture after prosthetic breast reconstruction. *Plast Reconstr Surg.* 1995;96:1119–1123; discussion 1124.
11. Wilflingseder P, Hoinkes G, Mikuz G. Tissue reactions from silicone implant in augmentation mammoplasties. *Minerva Chir.* 1983;38:877–880.