

Acoustic Wave Treatment For Cellulite - A New Approach

Katharina Russe-Wilflingseder, Elisabeth Russe

*Plastische Chirurgie und Laserzentrum Innsbruck
Haydnplatz 4, 6020 Innsbruck, Austria.
e-mail: katharina@russe.at*

Abstract.

Background and Objectives: Cellulite is a biological caused modification of the female connective tissue. In extracorporeal shockwave therapy (ESWT) pulses are penetrating into the tissue without causing a thermal effect or micro lesions, but leading to a stimulation of tissue metabolism and blood circulation, inducing a natural repair process with cell activation and stem cells proliferation. Recently ESWT treatment showed evidence of remodelling collagen within the dermis and of stimulating microcirculation in fatty tissue.

Study Design and Methods: The study was designed to assess acoustic wave treatment for cellulite by comparison treated vs. untreated side (upper-leg and buttock). Each individual served as its own control. 11 females with a BMI less than 30 and an age over 18 years were included. 6 treatments were given weekly with radial acoustic waves. Documentation was done before and 1, 4, 12 weeks after last treatment by standardized photo documentation, relaxed and with muscle contraction, measurement of body weight and circumference of the thigh, pinch test, and evaluation of hormonal status and lifestyle. The efficacy of AWT/EPAT was evaluated before and 1, 4, 12 weeks after last treatment. Patients rated the improvement of cellulite, overall satisfaction and acceptance. The therapist assessed improvement of cellulite, side effects and photo documentation treated vs. untreated side, before vs. after treatment. The blinded investigator evaluated the results using photo documentation right vs. left leg, before vs. after treatment in a frontal, lateral and dorsal view, relaxed and with muscle contraction.

Results: The improvement of cellulite at the treated side was rated by patients with 27,3% at week 4 and 12, by the therapist with 34,1% at week 4 and 31,2% at week 12 after the last treatment. The blinded investigator could verify an improvement of cellulite in an increasing number of patients with increasing time interval after treatment. No side effects were seen.

Conclusion: Radial acoustic waves are effective and safe to treat cellulite. The effect of treatment begins delayed and is first seen after 5 treatments. The improvement of cellulite increases continual up to 3 months. Patients' satisfaction and acceptance is high

Keywords: acoustic wave therapy, extracorporeal pulse activation technology, shock wave therapy, cellulite, subcutaneous adipose tissue

Abbreviations: AWT acoustic wave treatment, EPAT extracorporeal pulse activation technology, ESWT extracorporeal shock wave treatment, BMI body mass index

1. INTRODUCTION

1.1. BACKGROUND AND OBJECTIVES

Cellulite is no disease and has no association with morbidity or mortality. It is a biological caused modification of the female connective tissue. Cellulite is also described as orange peel syndrome, cottage cheese skin or synonymously also called nodular liposclerosis, cellulitic dermohypodermosis, sclerotic fibrous edematous panniculopathy, panniculosis of the dermis, cellulitic hypodermosis, gynoid lipodystrophy, hydrolipodystrophy, herniation of fat with hypodermic tension bands (Hexel et al 2006), panniculitis, liposclerosis, lipoedema, adiposis edematosa, dermopanniculosis deformans, status protrusus cutis (Terranova et al 2006). The so-called orange peel syndrome or cellulite describes the mattress phenomenon of the skin, which affects more than 90% of women of all ethnics. This appearance leads to an aesthetic problem and is an issue of concern to a great number of women worldwide.

The preferred hypotheses about the origin of cellulite include gender specific dimorphic skin architecture, altered connective tissue septae, vascular changes and inflammatory processes (Avram 2004). The septa of women's connective tissue are running perpendicularly to the dermis which may easily lead to fat herniation into the dermis. In contrary the men's crisscrossing fibrous tissue septae are running oblique to the dermis which prevents herniation (Nürnberg and Müller 1978). In addition women have about 20% more fat cells and the fat chambers have larger units being less resistant to herniation. Also hormones are etiological discussed as cellulite is far more common in females (85-98%), does not occur before puberty and is also seen in androgen deficient males (Bacci and Leibaschoff 2006). The pathophysiology behind postulates alterations to the adipose tissue causing fibrosclerosis in the connective tissue as a non inflammatory degenerative process. The enlarging of fat cells between the septa not only causes the dimpling effect, but also reduces microcirculation of blood and lymph which may lead to intracellular edema and reduced lymphatic drainage resulting in an increased storage of fat (Bacci and Leibaschoff 2006). Cellulite is an aesthetic problem mainly of back side, lower limbs, abdomen and the pelvic region (Rossi and Vergnanini 2000). Less elasticity of skin through aging also worsens the dimpling effect. This is a vicious cycle and the reason for ineffectiveness of sport and diets. In addition the connective tissue often becomes weaker with age and the 'mattress' appearance is in fact more visible. Therefore many women seek for medical advice in case of its unattractive appearance. A variety of different therapies for treating cellulite are described (Hexsel et al 2005, Rao et al 2005, Alster and Tehrani 2006, Kulick 2006, Pavicic et al 2006, Rawlings 2006, Reddy and Hantash 2009) with extreme differences in opinion (Terranova et al 2006). Efficacy of these strategies is low and an outstanding treatment for cellulite is still not known (Wanner and Avram 2008). Up to now there is no way to cure cellulite.

Acoustic wave technology is a new approach to improve the appearance of cellulite (Christ et al 2008). In AWT/EPAT pulses are penetrating into the tissue leading to a stimulation of tissue metabolism (Mariotto et al 2005) and blood circulation, inducing a natural repair process with cell activation and stem cells proliferation (Schaden et al 2007). AWT/EPAT which is an ESWT showed evidence of collagen remodeling within the dermis (Angehrn et al 2007) and of stimulating microcirculation in fatty tissue (Christ et al 2008). ESWT also is concluded to have a fibrosclerosis-preventing effect and is free of side effects (Siems et al 2005). Recently the clinical efficacy of AWT/EPAT was shown (Russe et al 2009).

1.2. TECHNOLOGY AND MECHANISM

Acoustic waves are pneumatically generated pressure waves. These waves are similar, but softer than the extracorporeal shock waves which have been used in urology for lithotripsy for more than 20 years. Compared to these shock waves the acoustic waves are longer and not focused but radial distributed. They penetrate up to 25 mm into the skin without thermal effect and reach the subcutaneous fat. The radial acoustic waves are proven in orthopedic treatments like tennis elbows and activation of muscle and connective tissue (Staples 2008, Hearnden 2009, Rompe 2009).

The pressure differences stimulate the tissue metabolism and the blood circulation leading to natural repair process with cell activation and stem cell proliferation. These variations are even enhanced by reflection especially at indurate fibrotic tissue (Siems et al 2005, Kuhn et al 2008).

2. MATERIAL AND METHODS

The study was designed to assess the treatment effect of AWT/EPAT by comparison of treated vs. untreated side (upper-leg and buttock). The treated side was chosen by dicing and not according to the wishes of the patients.

11 healthy women with a BMI less than 30 and an age over 18 years were included. Each woman was informed about the study (one side treated, one side untreated) and signed an informed consent. Exclusion criteria were acute inflammation of the treated area, intake of blood dissolvent drugs, performed liposuction or body lift within the last 5 years or pretreatments with endermology or any other body contouring device within the last 6 months. One thigh and bottom were treated and compared to the other untreated side serving as control.

Treatments were performed with the Acoustic Wave Module of the Effect family from Asclepion Laser Technologies, respectively D-Actor 50 from Storz Medical. A thin layer of ultrasound gel was applied to the treatment area first. The handpiece which emits the radial acoustic waves was moved with slight pressure in skin contact towards the lymph nodes and backwards without pressure, expecting a centripetal direction of treatment.

6 treatments were given every 7 days. The applicator with a 20 mm spot size was used at 3 bar respectively the maximal tolerated pressure and at 10 Hz. 20.000 pulses were applied for the upper leg and buttock (2000 pulses per 10 x 15 cm, 10 areas). Documentation was done before and at week 1, 4, 12 after the last treatment by standardized photo documentation, relaxed and with muscle contraction, measurement of body weight and circumference of the thigh (defined middle), pinch test (defined middle of the thigh) and evaluation of hormonal status and lifestyle (exercise, sports, diets). The efficacy of AWT/EPAT was evaluated before and at week 1, 4, 12 after the last treatment. Patients were asked to estimate the therapeutic success. The improvement of cellulite in terms of skin surface, reduction of dimples, texture of tissue, difference treated vs. untreated side, as well as overall satisfaction and acceptance of the therapy were expressed in % (0% = no change, 100% = complete recovery). The therapist assessed the improvement of cellulite in terms of skin surface, reduction of dimples, texture of tissue, difference treated vs. untreated side, as well as side effects of AWT/EPAT (erythema, hematoma, pain) and in addition photo-documentation treated vs. untreated side and before vs. after treatment. Also the therapist quantified the treatment effect in % from 0 to 100 (0% = no treatment effect, 100% = best possible result). A blinded investigator evaluated the results using only photodocumentation right vs. left leg and bottom, before vs. after treatment in a frontal, lateral and dorsal view, relaxed and with muscle contraction. Statistical comparisons were done by two sided t-tests (paired and unpaired).

3. RESULTS

Patients rated the mean improvement of cellulite at the treated side with 27,3% at week 4 and 12 after the last treatment. The therapist verified an improvement of cellulite in all patients between 25% and 50%, especially in view of tightening and smoothing of the skin. The therapist's mean rating of efficacy was 34,1% at week 4 and 31,2% at week 12 after the last treatment (Fig. 1).

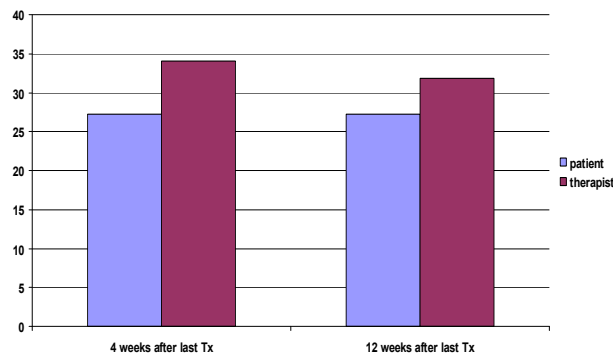


FIGURE 1. Percentage of average improvement rated by patient vs. therapist at week 4 and 12 after the last treatment

The blinded investigator saw differences between the two sides at week 4 on the posterior thigh in 2/11 patients (18,2%) and on the bottom in 4/11 patients (36,4%) and at week 12 in 6/11 patients (66,7%) for both areas (Fig. 2 & 3).

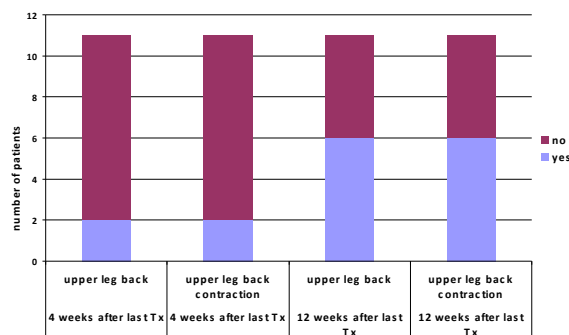


FIGURE 2. Blinded investigator's assessment of improvement given by yes or no answer for the backside of the upper leg relaxed and with muscle contraction.

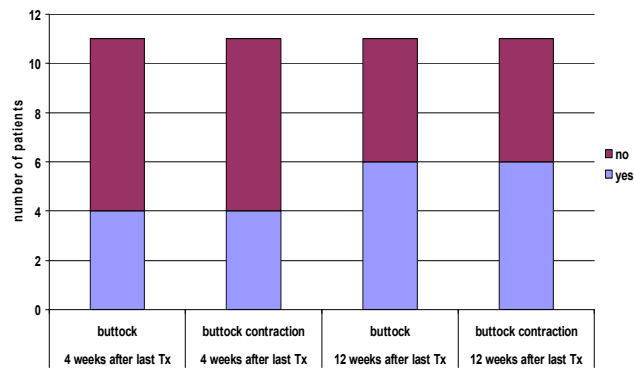


FIGURE 3. Blinded investigator's assessment of improvement given by yes or no answer for the buttock relaxed and with muscle contraction

The blinded investigator never failed to find the treated side although the evaluation was only done by standardized pre and post photo-documentation (Fig. 4).

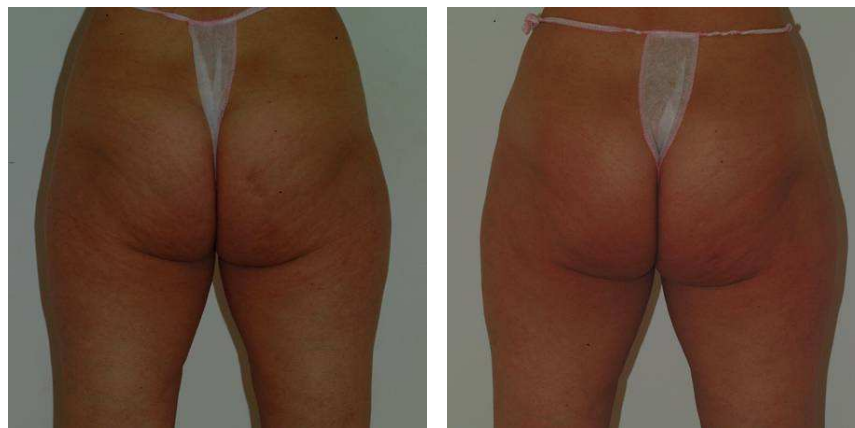


FIGURE 4. Fig.4: before (picture left) and 12 weeks (picture right) after last AWT of the right side. Both pictures show patient with muscle contraction

No side effects were seen. The comparison of the circumference of the upper leg treated vs. untreated side showed a borderline significant ($p = 0,091$) decrease on the treated side (Fig. 5) although a general loss of body weight ($p = 0,054$) was seen.

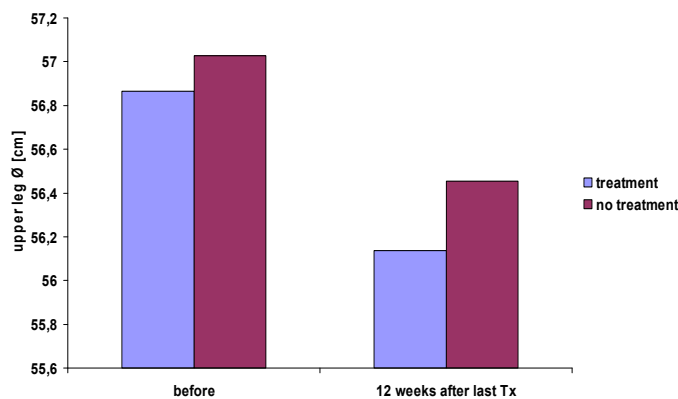


FIGURE 5. Average measurement of the circumference of the upper leg (treated vs untreated side) before and at week 12 after last Tx

There was no significant difference in the pinch test (Tab. 1).

TABLE 1. Body weight, and changes of treated and untreated upper leg quantified by circumferences and thickness of subcutaneous fat estimated by pinch test before and 12 weeks after last Tx (n=11).

		pre Tx	post Tx	p-value	
body weight	kg	67,6	66,06	0,054	
upper leg Ø	cm	56,56	56,14	0,091	treated
pinch test	cm	3,77	4,05	0,245	treated
upper leg Ø	cm	57,03	56,45	0,221	untreated
pinch test	cm	3,75	4,04	0,250	untreated

4. DISCUSSION

The AWT/EPAT study was designed as a single-center unblinded controlled clinical study to evaluate the efficacy of acoustic waves in the treatment of cellulite. To exclude all other interacting factors beside acoustic waves all individuals served as their own control as only one leg and buttock was treated and the other side remained without any treatment being the reference.

Changes by treatment were estimated by patients themselves, the therapist and a blinded investigator. All three evaluators verified in most patients an improvement of dimples and skin appearance. 2 of 11 individuals saw no effect 4 and 12 weeks after the last treatment. In these 2 women also the blinded investigator could not differ between treated and untreated side. 9 out of 11 individuals saw a treatment effect and quantified the improvement in the same extent 4 and 12 weeks after the last treatment (Fig.1). In 6 out of 11 individuals the treatment effect was obvious and the difference between treated and untreated side was unacceptable for these individuals. All 6 asked for treatment of the untreated side.

The rating of patients differed from the rating of the therapist. The patients were not able to see their backside and therefore could not evaluate the improvement entirely easy. Not surprisingly the therapist always estimated best. The blinded investigator could identify the treated side in 54,5% (6 out of 11 patients) by evaluation of the standardized photodocumentation only. It is remarkable that the blinded investigator never failed to identify the treated side in those cases where side differences were seen.

5. CONCLUSION

AWT/EPAT is a new approach in the treatment of cellulite. It is a local therapy easy to handle, non invasive and free of side effects. The effect of treatment begins delayed usually not before 5 treatments. The improvement of cellulite increases continual up to 3 months. Patients' satisfaction and acceptance is high.

ACKNOWLEDGMENTS

The equipment for this study was provided by Aselecion Laser Technologies. The authors thank Gabi Zimmermann, Dipl.-Phys., from Aselecion Laser Technologies, Jena, Germany for the technical support.

REFERENCES

- Alster TS, Tehrani M. Treatment of cellulite with optical devices: an overview with practical considerations. *Lasers Surg Med.* 2006;38:727-30
- Angehrn F, Kuhn C, Voss A. Can cellulite be treated with low-energy extracorporeal shock wave therapy? *Clin Interv Aging.* 2007;2:623-30.
- Avram MM. Cellulite: a review of its physiology and treatment. *J Cosmet Laser Ther* 2004;6:181-5.

- Bacci PA, Leibaschoff G. Pathophysiology of Cellulite In: Goldman MP, Bacci PA, Leibaschoff G, Hexsel D, Angelini F. Cellulite pathophysiology and treatment, Taylor & Francis 2006;41-71.
- Christ C, Brenke R, Sattler G, Siems W, Novak P, Daser A. Improvement in skin elasticity in the treatment of cellulite and connective tissue weakness by means of extracorporeal pulse activation therapy. *Aesthet Surg J*. 2008;28:538-44.
- Hearnden A. Extracorporeal shock wave therapy in chronic calcific tendonitis of the shoulder is it effective? *Acta Orthop Belg*. 2009;75:25-31
- Hexsel D, De Oliveira Dal’Forno T, Cignachi S. Definition, clinical aspects, associated conditions and differential diagnosis of cellulite. In: Goldman MP, Bacci PA, Leibaschoff G, Hexsel D, Angelini F. Cellulite pathophysiology and treatment, Taylor & Francis 2006;7-28.
- Hexsel D, Orlandi C, Zechmeister do Prado D. Botanical extracts used in the treatment of cellulite. *Dermatol Surg*. 2005;31:866-72
- Kuhn C, Angehrn F, Sonnabend O, Voss A. Impact of extracorporeal shock waves on the human skin with cellulite: A case study of an unique instance. *Clin Interv. Aging* 2008;3:201–10
- Kulick M. Evaluation of the combination of radio frequency, infrared energy and mechanical rollers with suction to improve skin surface irregularities (cellulite) in a limited treatment area. *J Cosmet Laser Ther*. 2006;8:185-90
- Mariotto S, Cavalieri E, Amelio E, Ciampa AR, de Prati AC, Marlinghaus E, Russo S, Suzuki H. Extracorporeal shock waves: from lithotripsy to anti-inflammatory action by NO production. *Nitric Oxide*. 2005;12:89-96.
- Nürnberg F, Müller G. “So-called cellulite: an invented disease”, *J Dermatol Surg Oncol* 1978;4:221-9.
- Pavicic T, Borelli C, Korting HC. Cellulite – das größte Hautproblem des Gesunden? Eine Annäherung. *J Dtsch Dermatol Ges*. 2006;4:861-70
- Rao J, Gold MH, Goldman MP. A two-center, double-blinded, randomized trial testing the tolerability and efficacy of a novel therapeutic agent for cellulite reduction. *J Cosmet Dermatol*. 2005;4:93-102
- Rawlings AV. Cellulite and its treatment. *Int J Cosmet Sci* 2006;28:175-90
- Reddy BY, Hantash BM. Emerging technologies in aesthetic medicine. *Dermatol Clin* 2009;27:521-7
- Rompe JD. Home training, local corticosteroid injection, or radial shock wave therapy for greater trochanter pain syndrome. *Am J Sports Med*. 2009;37:1981-90
- Rossi AB, Vergnanini AL. Cellulite: a review. *J Eur Acad Dermatol Venereol* 2000;14:251–62
- Russe E, Juric M, Russe-Wilflingseder K. Acoustic wave treatment for cellulite – a new approach. *Lasers Surg Med Suppl*. 2009;21:81-82
- Schaden W, Thiele R, Köppl C, Pusch M, Nissan A, Attinger CE, Maniscalco-Theberge ME, Peoples GE, Elster EA, Stojadinovic A. Shock wave therapy for acute and chronic soft tissue wounds: a feasibility study. *J Surg Res*. 2007;143:1-12
- Siems W, Grune T, Voss P, Brenke R. Anti-fibrosclerotic effects of shock wave therapy in lipedema and cellulite. *BioFactors* 2005;24:275–82
- Staples MP. A randomized controlled trial of extracorporeal shock wave therapy for lateral epicondylitis (tennis elbow). *J Rheumatol*. 2008;35:2038-46
- Terranova F, Berardesca E, Maibach H. Cellulite: nature and aetiopathogenesis. *Int J Cosmet Sci* 2006;28:157-67
- Wanner M, Avram M. An evidence-based assessment of treatments for cellulite. *J Drugs Dermatol*. 2008;7:341-5