

See discussions, stats, and author profiles for this publication at: <https://www.researchgate.net/publication/327024501>

# Effects of the extracorporeal shock wave therapy on the skin: an experimental study

Article in *Lasers in Medical Science* · August 2018

DOI: 10.1007/s10103-018-2612-8

CITATIONS

0

READS

282

11 authors, including:



**Rodrigo Marcel Valentim da Silva**

Universidade Federal do Rio Grande do Norte

46 PUBLICATIONS 36 CITATIONS

[SEE PROFILE](#)



**Esteban Ignacio Fortuny**

Universidad Finis Terrae

5 PUBLICATIONS 2 CITATIONS

[SEE PROFILE](#)



**Ciro Dantas Soares**

University of Campinas

31 PUBLICATIONS 34 CITATIONS

[SEE PROFILE](#)

Some of the authors of this publication are also working on these related projects:



Treatment of Lymphedema [View project](#)



FGF2/FGFR1 pathway in oral and odontogenic lesions [View project](#)



# Effects of the extracorporeal shock wave therapy on the skin: an experimental study

Thayná Melo de Lima Morais<sup>1</sup> · Patrícia Froes Meyer<sup>2</sup> · Liliâne Santos de Vasconcellos<sup>2</sup> · Julio Costa e Silva<sup>2</sup> · Ito Ferreira e Andrade<sup>2</sup> · Vinicius Alves Freire de Farias<sup>2</sup> · Igor Candido da Silva<sup>2</sup> · Roberta Marinho Falcão Gondim Araújo<sup>3</sup> · Rodrigo Marcel Valentim da Silva<sup>3</sup> · Esteban Fortuny Pacheco<sup>4</sup> · Ciro Dantas Soares<sup>1</sup>

Received: 7 May 2018 / Accepted: 7 August 2018  
© Springer-Verlag London Ltd., part of Springer Nature 2018

## Abstract

Extracorporeal shock wave therapy (ESWT) has been extensively studied for its multiple biological properties, and although it is widely applied in esthetical procedures, little is known about its effects on the epidermis and dermis. In this study, a histological and immunohistochemical study of the effects of ESWT was performed on rat skin. Forty-five female rats were treated with one or two sessions of ESWT and sacrificed on days 1, 7, 14, and 21 after treatment. The samples were histologically processed and then morphometric analyses were performed to assess the epidermis, dermis, and subcutaneous fat tissue thickness. Immunohistochemical reactions were also performed against the antibodies: basic fibroblastic growth factor (FGF2), its receptor (FGFR1), and  $\alpha$ -smooth muscle actin. Slides were scanned and digitally assessed, to determine the microvessel density (MVD) and digital scoring of the immunohistochemical staining. The results showed that ESWT produced a significantly higher collagen content, MVD, and epidermis and dermis thickness than the control, non-treated group. Both in epidermis and dermis, FGF2 was overexpressed in the ESWT-treated groups, whereas FGFR1 was increased only in the group treated with two ESWT sessions at 21-days post-treatment. The ESWT-treated groups have also shown diminished thickness of subcutaneous fat tissue. In conclusion, ESWT induces neocollagenesis and neoangiogenesis, and upregulates the FGF2 expression, particularly in the groups treated with two sessions. Furthermore, it was demonstrated that overexpression of FGF2 on skins treated with ESWT seems to be a key role on its mechanism of action.

**Keywords** Extracorporeal shock wave therapy · Fibroblast growth factor 2 · Collagen · Inflammatory cells

---

Thayná Melo de Lima Morais and Liliâne Santos de Vasconcellos contributed equally to this work.

**Electronic supplementary material** The online version of this article (<https://doi.org/10.1007/s10103-018-2612-8>) contains supplementary material, which is available to authorized users.

✉ Ciro Dantas Soares  
ciro.dss@gmail.com; c162617@g.unicamp.br

- <sup>1</sup> Oral Pathology Section, Department of Oral Diagnosis, Piracicaba Dental School, University of Campinas (UNICAMP), Av. Limeira 901, Piracicaba, SP 1314-903, Brazil
- <sup>2</sup> Physiotherapy Department, Potiguar University, Natal, Brazil
- <sup>3</sup> Medicine Department, Potiguar University, Natal, Brazil
- <sup>4</sup> Physiotherapy Department, Federal University of Rio Grande do Norte, Natal, Brazil

## Introduction

Esthetic procedures are utilized common resource in the cosmetic dermatology/dermatologic surgery practice [1]. Currently, non-invasive rejuvenation therapies are widely used to provide neocollagenesis and adequate dermal blood supply. As a consequence, such therapies are able to promote proliferation and renovation of dermal cells, blood vessels, and extracellular matrix modulation [2]. Therefore, several growth factors have been studied as responsible for biological stimulation of neocollagenesis and neoangiogenesis [3, 4]. It has been previously demonstrated that the radiofrequency therapy modulates these biological events on rat skin through stimulation and activation of the basic fibroblast growth factor (FGF2) and its receptors (FGFR1) [5].

The FGF2 is a multifunctional growth factor mainly recognized by its angiogenic and mitogenic properties [6–8].

Although FGF2 has been extensively studied in morphogenesis, inflammation, tumorigenesis, and tissue repair, few studies have been focused in its biological activities during esthetic procedures. It is well recognized that FGF2 is a potent dermal stimulator, and experimental models have demonstrated its effect in deposition and maturation of collagen fibers [9, 10]. The activation of the FGF pathway depends of the binding with their four receptors (FGFR1–4) [11]. Therefore, it was demonstrated that FGFR1 is the receptor with the highest affinity for FGF2 [12]. Thus, we hypothesize that the coexpression of FGF2 and FGFR1 may be associated with high activities in the different tissues.

Extracorporeal shock wave therapy (ESWT) has been extensively studied for its multiple biological properties, mainly by modulating the repair process [13]. The basis of this therapy consists in the use of equipment able to generate a sequence of high-amplitude sound waves that reverberate three-dimensionally. Previous studies have reported that ESWT promotes angiogenesis and suppresses the inflammatory response [14–16]; however, the molecular mechanisms that cause these biological events are poorly understood.

Based on a recent proposal of evidence-based esthetic dermatology practice [17], the present study aimed to investigate the effects of ESWT on modulating the expression of FGF2 and FGFR1 in the skin. In addition, the neoangiogenesis and collagen deposition were evaluated.

## Material and methods

### Ethical considerations

The experimental protocol applied in this study followed the Animal Experimentation Code of Ethics and the Brazilian College of Animal Experimentation guidelines. Approval was granted by the ethics institutional review board at Potiguar University, Natal, RN, Brazil (CEP/UNP; registration number 002/2017).

### Subjects and treatment protocol

Forty-five female rats were randomly selected for this study and divided into six groups according to the established treatment and experimental period, as described in Table 1. During the experimental period, the subjects received water and food ad libitum, and were kept in an environment with controlled light (cycles of 12 h light/dark), ventilation, and temperature (24 °C).

### Extracorporeal shock wave therapy

ESWT was applied without anesthesia using a Storz Duolith SD1 device (STORZ MEDICAL AG, Switzerland) in one or

**Table 1** Experimental groups, ESWT protocol, and experimental periods (time of euthanasia)

Group	Treatment (ESWT)	Experimental period (euthanasia)
Control ( <i>n</i> = 15)	No treatment	1, 7, 14, and 21 days
G1 ( <i>n</i> = 6)	One session	1 day
G2 ( <i>n</i> = 6)	One session	7 days*
G3 ( <i>n</i> = 6)	Two sessions*	7 days*
G4 ( <i>n</i> = 6)	Two sessions*	14 days*
G5 ( <i>n</i> = 6)	Two sessions*	21 days*

\*With interval of 48 h between the sessions, time after the first session of ESWT

two therapeutic sessions with 48-h interval in-between. The settings were 500 impulses (pressure 2 bar, frequency 4 Hz) with an average energy flux density of 0.13 mJ/mm<sup>2</sup>.

### Morphological analyses

Sequential 5- $\mu$ m sections were stained with HE, picrosirius red, and Masson's trichrome. Two trained pathologists performed the quantitative morphological analyses, considering ten fields of high amplification for each subject. The subcutaneous fat layer, epidermis, and dermis thickness and the collagen content were measured with a Software Leica Application Suite, version 2.8.1 (Leica Microsystems GmbH, Wetzlar, Germany). Inflammatory cells were manually counted.

Total, type I, and type III collagen content were assessed as follows:

Total collagen content was assessed in the Masson trichrome-stained slides, considering the areas of blue stain divided by the total-analyzed area, using the formula (total collagen content = blue-stained areas  $\div$  total area analyzed  $\times$  100). Collagen content was expressed in percentage.

Type III collagen content was assessed in picrosirius red-stained slides and analyzed under polarization, considering the areas of green stain, and the percentage of collagen content was obtained using the formula (type III collagen content = green-stained areas  $\div$  total-analyzed area  $\times$  100). Type I collagen content was assessed using the formula (type I collagen content = green-stained areas  $\div$  total-analyzed area  $\times$  100). The data was expressed in percentage.

### Immunohistochemical assay

Paraffin-embedded 3- $\mu$ m sections were submitted to antigen retrieval with sodium citrate buffer solution (10 mM, pH 6.0)

and incubated with primary antibodies against FGF2 (polyclonal, dilution 1:50, Santa Cruz Biotechnology, Santa Cruz, CA, USA), FGFR1 (polyclonal, dilution 1:50, Santa Cruz Biotechnology, Santa Cruz, CA, USA), and smooth muscle actin (clone 1A4, dilution 1:400, Dako, Carpinteria, CA, USA) according to the manufacturer's protocol. The secondary antibody (EnVision FLEX Systems; Dako, Carpinteria, CA, USA) was conducted for 30 min, and staining was performed using diaminobenzidine (DAB). Finally, the slides were counterstained with Carazzi's hematoxylin and mounted.

### Immunohistochemical analysis

The slides were scanned into high-resolution images with the Aperio Scanscope CS Slide Scanner (Aperio Technologies Inc., Vista, CA, USA) and were digitally assessed for establishment of the immunoexpression scores for all antibodies using the Pixel Count V9 algorithm software (Aperio Technologies Inc). Scores ranged from 100 to 300 as previously described [18]. The microvessel density (MVD) was obtained with the Microvessel Analysis V1 software (Aperio Technologies Inc) with the following input parameters: mode, include incomplete vessels; vessel type mode, irregular/long vessels; filtering/smoothing level, 2; dark staining threshold, 200; light staining threshold, 210; region joining parameter, 7; vessel completion parameter, 7; minimum vessel area threshold, 0; maximum vessel area threshold, 200,000; maximum vessel wall thickness, 10; and clear area intensity, 240. The MVD was expressed in (vessels/mm<sup>2</sup>) and scored as follows: (1) no vessels detected, (2) up to 5, (3) up to 10, and (4) more than 10.

### Statistical analysis

Initially, the data were submitted to normality testing (Kolmogorov-Smirnov and Shapiro-Wilk tests). The Kruskal-Wallis test was used to compare the mean scores used in the histomorphometric analyses and MVD. Two-way ANOVA was then performed to compare the mean of the immunohistochemical staining. In these analyses, the control group was not included due to the insignificant expression of the markers analyzed, which were negative or very weak for control animals.  $P < 0.05$  was considered as significant.

## Results

### ESWT induces epidermal hyperplasia and cellular proliferation

Figure 1 shows the morphological changes in the epidermis and dermis of the skins treated with ESWT. Overall, morphological

analyses revealed that skins, either treated or not, showed epidermis and dermis of normal aspects (Fig. 1a). The epidermis seemed regular with 3–5 layers of keratinocytes; however, some changes were observed in the treated groups, with epidermal hyperplasia and increased number of layers, acanthosis and less common, elongated, and thick downward epidermis projection. The epidermis thickness was higher in the G2, G3, G4, and G5 groups than in the control (Fig. 1b), with a peak in group G3 ( $P < 0.0001$ ).

The dermis thickness was significantly higher in all groups treated with ESWT in comparison to control group (Fig. 1c,  $P < 0.0001$ ). With exception of the G1 group, in which one session of ESWT was delivered, and no differences were noted with the control group. In addition to the higher dermal thickness, it was also possible to detect an increased number of inflammatory cells, dermal fibroblasts, and other stromal cells (Fig. 1d). Concerning the inflammatory events, was performed a quantitative analysis of the mononuclear cells was performed, and the ESWT-treated groups demonstrated a significantly higher number of inflammatory cells than the control group ( $P < 0.0001$ ). This was more evident 24 h and 7 days after treatment.

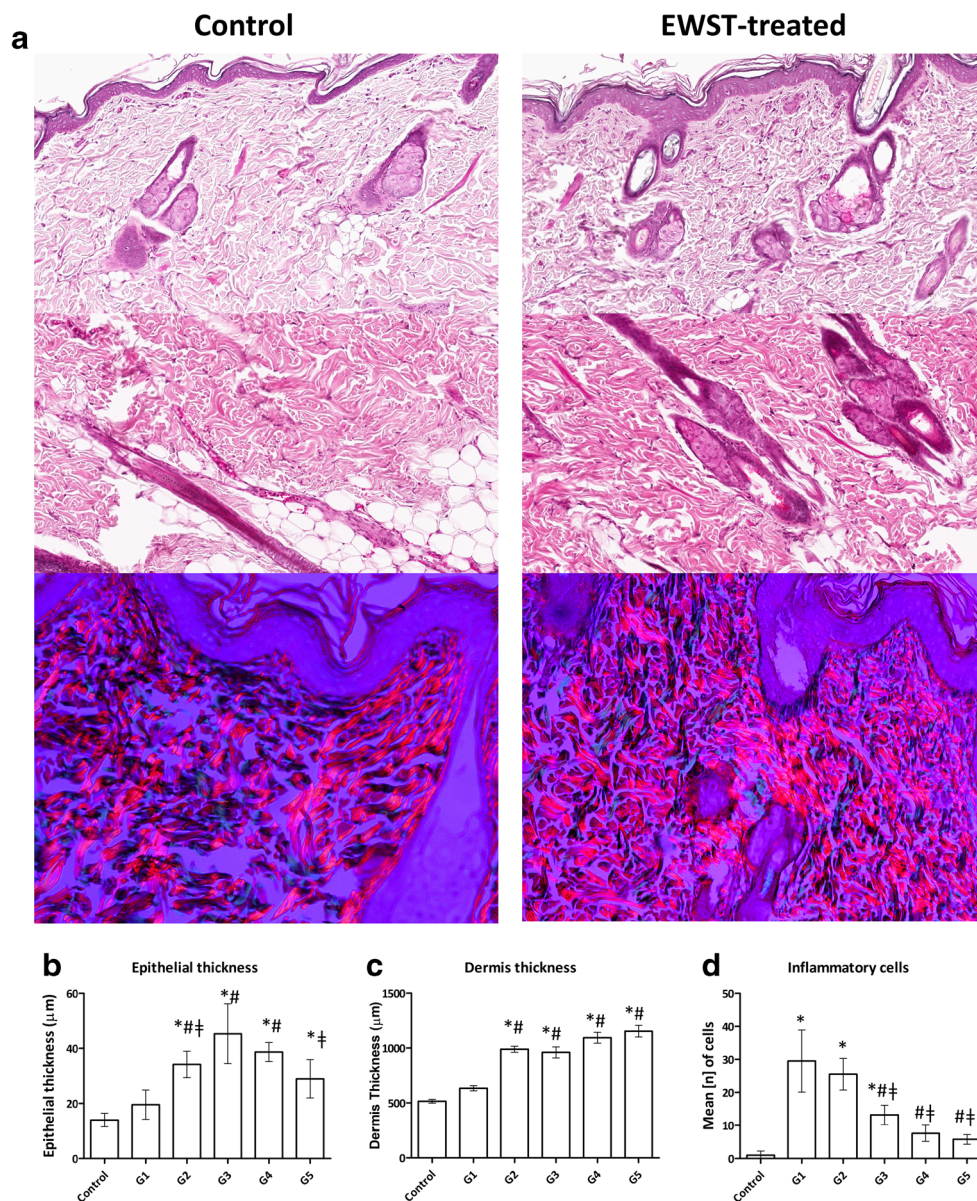
### Higher collagen densities were identified on skins treated with ESWT than the values found in control group

The collagen content was significantly higher in ESWT-treated skins than in the control group. The results are summarized in Table 2. Higher content of type I collagen was more observed in G3, G4, and G5 groups than in the control, non-treated group, and in G1 with only one ESWT-therapeutic session ( $P < 0.0001$ ). A reduction on the subcutaneous fat layer was also observed (Fig. 1a, red arrows, and Table 2. The subcutaneous fat layer thickness was significantly reduced in G3, G4, and G5 ( $P < 0.0001$ ).

### ESWT is associated with FGF-FGFR1 pathway activation and induces neoangiogenesis

Figures 2 and 3 display representative images of FGF2 and FGFR1 expressions of ESWT-treated skins. Both FGF2 and FGFR1 were weakly expressed or absent in the skins from the control group. FGF2 demonstrated a cytoplasmic expression in all layers of the epidermis in the G3 skins than in G1, G2, and G5. In these last groups, a pattern of individual cells expressing FGF2 was observed. Dermal cells such as fibroblasts, endothelial, and hair follicle cells demonstrated higher expression of FGF2 in G3, G4, and G5 (Fig. 2). The total collagen content was significantly increased in G3 in comparison to the other groups ( $P = 0.0221$ ). Both in epidermis and dermis, FGFR1 was equally expressed within the groups (Fig. 3).

**Fig. 1** Histological and histomorphometric analyses. **a** ESWT-treated groups with higher epithelial thickness and higher number of fibroblasts, and inflammatory cells in the dermis. Higher number of type I collagen fibers (orange) was also observed in the ESWT-treated groups. **b** Epithelial thickness; \*statistically significant difference from the control, #statistically significant difference from G1, †statistically significant difference from G3, ANOVA,  $P < 0.0001$ . **c** Dermis thickness; \*statistically significant difference from the control, #statistically significant difference from G1, ANOVA,  $P < 0.0001$ . **d** Mean of inflammatory cells; \*statistically significant difference from control group, #statistically significant difference from G1, †statistically significant difference from G2, ANOVA,  $P < 0.0001$



Only G5 showed a significantly higher FGFR1 expression in the epidermis than in the other groups ( $P = 0.0239$ ). MVD was significantly higher in G3 and G4 than in G1 and G2 groups ( $P = 0.0003$ ).

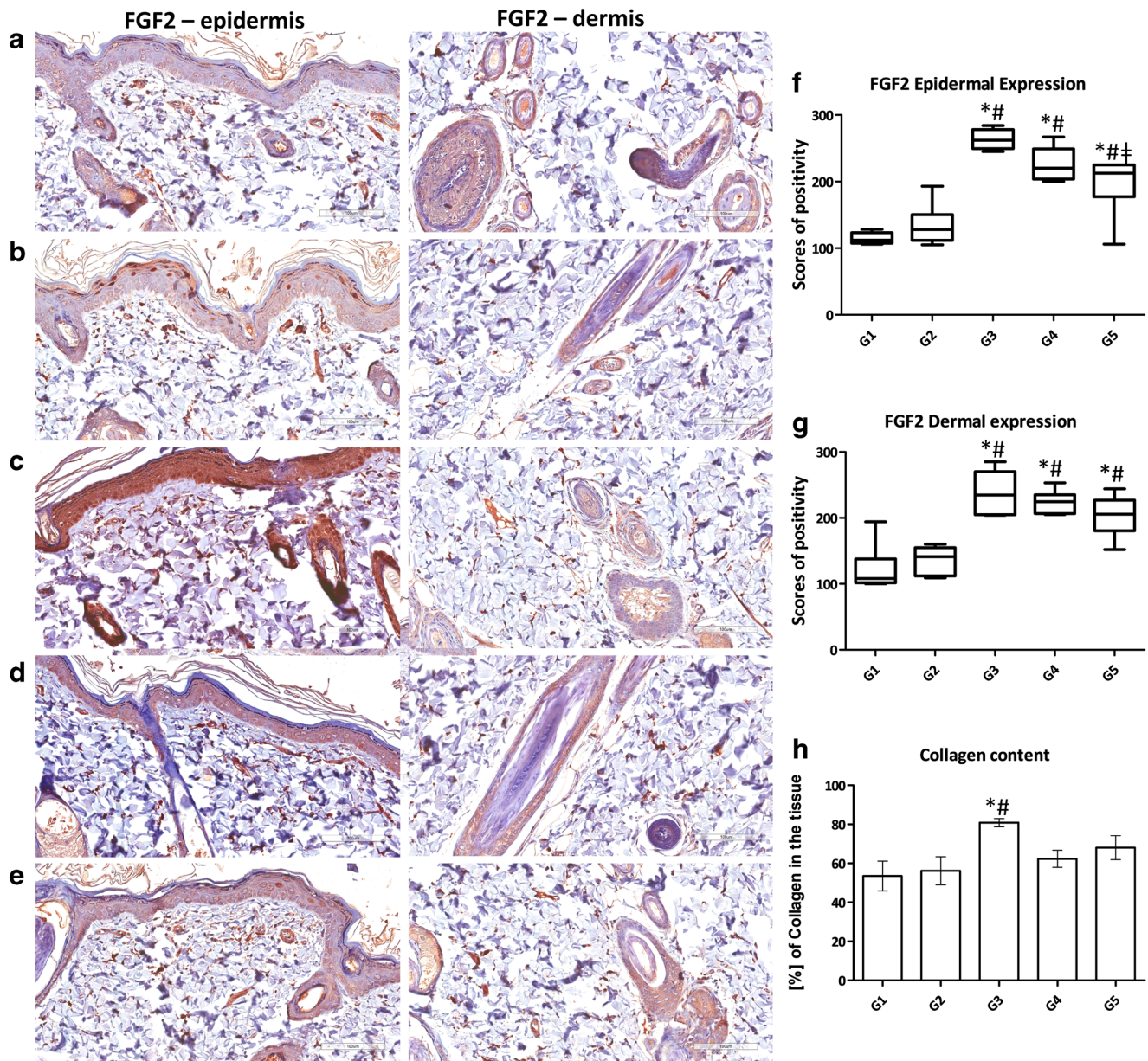
## Discussion

Esthetic procedures are widely utilized with the purpose of increasing skin metabolism and inflammatory response

**Table 2** Type I and type III collagen content and thickness of the subcutaneous fat layer in skin tissues treated with ESWT

	Control	G1	G2	G3	G4	G5
Type I collagen	78.24% <sup>a</sup>	79.78% <sup>a</sup>	88.32% <sup>b</sup>	89.56% <sup>b</sup>	88.92% <sup>b</sup>	88.02% <sup>b</sup>
Type III collagen	21.76% <sup>a</sup>	20.22% <sup>a</sup>	11.68% <sup>b</sup>	10.44% <sup>b</sup>	11.08% <sup>b</sup>	11.98% <sup>b</sup>
Thickness of the subcutaneous fat layer	266.7 μm <sup>a</sup>	227.5 μm <sup>a</sup>	126.3 μm <sup>b</sup>	118.1 μm <sup>b</sup>	150.4 μm <sup>b</sup>	132.4 μm <sup>b</sup>

Means with different letters indicate a significant difference between the groups. For all three analyses, the value of  $P$  was  $< 0.0001$  (two-way ANOVA)



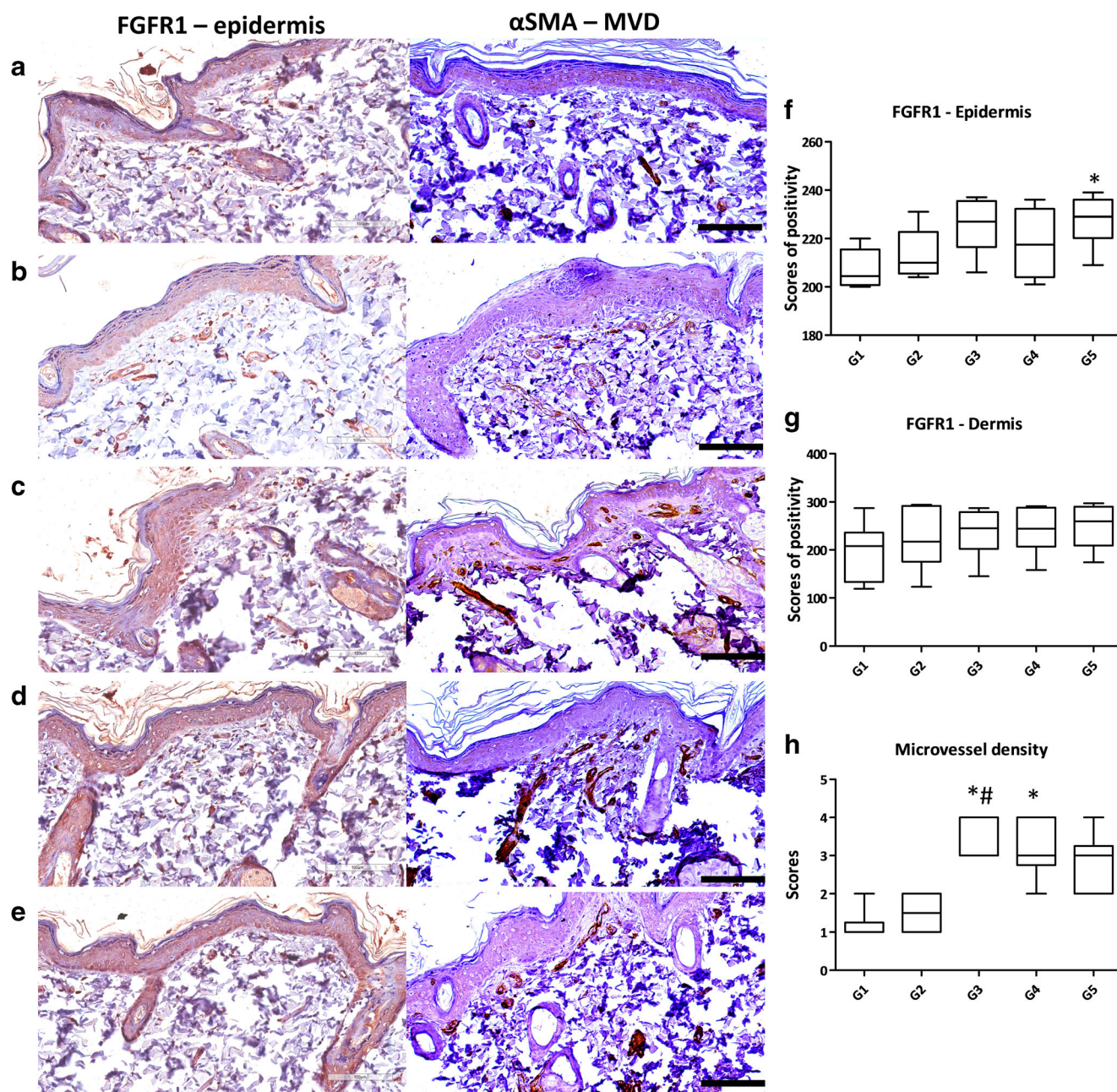
**Fig. 2** FGF2 immunoeexpression in ESWT-treated groups. **a** G1. **b** G2. **c** G3. **d** G4. **e** G5. **f** Graphical representation of FGF2 epidermal expression; \* statistically significant difference from G1, # statistically significant difference from G2, † statistically significant difference from G3, ANOVA,  $P < 0.0001$ . **g** Graphical representation of FGF2 dermal

expression; \* statistically significant difference from G1, # statistically significant difference from G2, ANOVA,  $P < 0.0001$ . **h** Average of the total collagen content, quantified by the Masson trichrome staining. \* Statistically significant difference from G1, # statistically significant difference from G2, ANOVA,  $P = 0.0221$

[1, 2]. However, the biological mechanisms that induce such processes are little known, and studies for the establishment of safe metabolism stimulation techniques are highly recommended [3, 4]. The extracorporeal shock wave therapy (ESWT) is recognized for its ability to improve the metabolic activity of various cell types, including dermal and epidermal cells [13–16]. It has been previously demonstrated that ESWT improves the growth factor levels of tendon-bone junction, consequently improving the neovascularization [14]. However, the molecular mechanisms involved in these processes are still being investigated. Aiming to understand the

chronological effects of the ESWT, sequential analyses of the treated tissues were performed.

The subjects were divided into five groups, with one or two sessions of ESWT with skin removal for histopathological analyses at 1, 7, 14, and 21 days after the treatment. Thus, it was possible to analyze the chronological effects of the ESWT. Overall, we observed that all subjects survived the ESWT and no side effects were seen. The ESWT caused some minor changes in the epidermis and dermis of rat skins. When treated with one ESWT application, the events were very subtle, and the two-ESWT application has demonstrated the most



**Fig. 3** FGFR1 immunopositivity and microvessel density (MVD) assessed by counting the vessels positive for  $\alpha$ -smooth muscle actin in ESWT-treated groups. **a** G1. **b** G2. **c** G3. **d** G4. **e** G5. **f** Graphical representation of FGFR1 epidermal expression; \*statistically significant difference from G1, ANOVA,  $P=0.0239$ . **g** Graphical representation of

FGFR1 dermal expression; no statistically significant differences noted, ANOVA,  $P=0.5078$ . **h** Scores of MVD. \*Statistically significant difference from G1, #statistically significant difference from G2, Kruskal-Wallis test,  $P=0.0003$

relevant biological events, highlighting its dose-dependent effect. This concurs with previous clinical studies on cellulite [19] and in vitro research [20].

The higher epidermal and dermal thickness observed in the treated groups revealed that this stimulatory effect is dose-dependent, and consequently, it warrants the use of ESWT as a therapy with rejuvenation purpose. Indeed, our group has previously demonstrated that RF treatment [5], a known rejuvenation technique that also causes epidermal and dermal

thickness increase as a consequence of the therapy's stimulatory effects.

Rosso et al. [21] revised the literature about the mechanical effects of ESWT and consequently collagen-deposition stimulation. The authors conclude that ESWT is a therapy that causes cellular proliferation, including fibroblasts and a consequent increase in type I collagen deposition. Also, Vetrano et al. [22] has demonstrated that ESWT increases the cellular proliferation and type I collagen deposition on cultured human

tenocytes. Analyzing the picrosirius red stain under light microscopy with polarization, the visualization of highly birefringent thick (orange-red) and thin (green-yellow) collagen fibers was possible. Thus, in this study, the type I collagen quantification in the ESWT-treated skins was performed. A higher type I collagen content in the ESWT-treated skins was observed, corroborating with previously mentioned researches. As a consequence of the ESWT, we expect that in the clinical practice, it can promote the improvement of the cutaneous aspect, preventing the signs of aging, and skin flaccidity. These effects are expected due to the microscopical differences observed in treated and non-treated animals.

Although the levels of type I collagen have been modified by ESWT-treatment, the total collagen content assessed by Masson's trichrome stain did not change. Only G3 showed a significantly increased content of total collagen in comparison to other groups. In fact, some studies have demonstrated that the ESWT is able to induce fibroblast proliferation and change the gene expression of type I and III collagens [23, 24]. This may be explained by higher indexes of collagen remodeling than neocollagenesis; however, additional studies are encouraged to clarify these specific questions.

Angiogenic growth factors are important for dermal supply increase, acting as stimulators of neovascularization [2]. Among these, the FGF2 was recognized as a relevant skin growth factor [6, 7]. Wang et al. [25] have demonstrated that ESWT was able to induce overexpression of angiogenic markers including vessel endothelial growth factor (VEGF) and endothelial nitric oxide synthase (eNOS), and also higher endothelial cell proliferation during repair of the tendon-bone junction in rats. Other studies have shown that ESWT induces higher expression of VEGF during wound healing [26]. These findings broadly corroborate with previous studies, as two applications of ESWT on rat skins increased the MVD, inflammatory infiltrate, and stimulated cellular proliferation. In addition, this study demonstrated that ESWT induces FGF2 overexpression, substantiating previous studies that showed FGF2 upregulation in epigastric skin flap [26], lymphoedema [27], and bone repair [28] rat models. These results obtained in different animal models warrant future clinical studies and allow more elaborated findings. Based on these previous experimental studies [20, 25, 28], we selected the settings of 500 impulses (pressure 2 bar, frequency 4 Hz) with an average energy flux density of 0.13 mJ/mm<sup>2</sup>. In clinical practice, due to increased local blood flow, hyperemia may appear at the site of application as a consequence of ESWT.

Concerning rejuvenation techniques, ESWT has been utilized for the treatment of cellulite, localized adiposity, and skin flaccidity [29, 30]. We provided, in this study, additional evidence that it is a safe therapy and can be indicated for rejuvenation approach. With respect to laser-based rejuvenation technique, the most common treatment is ablative resurfacing

with a carbon dioxide (CO<sub>2</sub>) or Er:YAG laser. It appears that the mechanism of effect is very similar to the biological effects observed with ESWT, such as thermal damage to the lower layers of the dermis. Causing a collagen production but does not injure the epidermis [31–33]. However, additional studies are highly recommended to attempt to clarify these related aspects.

Thus, this study suggests that the ESWT modulates FGF2 activity of and its FGFR1 ligand in the epidermis and dermis, consequently stimulates neocollagenesis and neoangiogenesis. It was also noted that ESWT may be an alternate expedient for subcutaneous fat layer reduction. Hence, the present study provides original data about the biological effects of ESWT on the skin of rats, and the confirmation of such data in clinical studies is highly recommended.

**Funding** This study was funded by the Brazilian National Council of Scientific and Technological Development (CNPq) research fellowship (registered under numbers 145722/2013-9, 101367/2014-7, and 117277/2014-2 to C.D.S.) and by FAPESP (São Paulo Research Foundation) for the Ph.D. fellowship to C.D.S. (#2015/25905-1).

## Compliance with ethical standards

This experimental protocol followed the guidelines of the Animal Experimentation Code of Ethics and Brazilian College of Animal Experimentation and was duly approved by the Ethics Committee of Potiguar University, Laureate International Universities (protocol number 002/2017).

**Conflict of interest** The authors declare that they have no conflicts of interest.

**Informed consent** Not applicable. This article does not contain any studies with human participants.

## References

1. Nobile V, Michelotti A, Cestone E (2016) A home-based eyebrows lifting effect using a novel device that emits electrostatic pulses containing RF energy, resulting in high frequency, low level transdermal microcurrent pulsations: double blind, randomized clinical study of efficacy and safety. *J Cosmet Laser Ther* 18:234–238. <https://doi.org/10.3109/14764172.2016.1156704>
2. Widgerow AD, Fabi SG, Palestine RF et al (2016) Extracellular matrix modulation: optimizing skin care and rejuvenation procedures. *J Drugs Dermatol* 15:s63–s71
3. Fitzpatrick RE, Rostan EF (2003) Reversal of photodamage with topical growth factors: a pilot study. *J Cosmet Laser Ther* 5:25–34
4. Scialfani AP, McCormick SA (2012) Induction of dermal collagenesis, angiogenesis, and adipogenesis in human skin by injection of platelet-rich fibrin matrix. *Arch Facial Plast Surg* 14:132–136. <https://doi.org/10.1001/archfacial.2011.784>
5. Meyer PF, de Oliveira P, Silva FKBA et al (2017) Radiofrequency treatment induces fibroblast growth factor 2 expression and subsequently promotes neocollagenesis and neoangiogenesis in the skin tissue. *Lasers Med Sci* 32:1727–1736. <https://doi.org/10.1007/s10103-017-2238-2>



6. Bikfalvi A, Klein S, Pintucci G, Rifkin DB (1997) Biological roles of fibroblast growth factor-2. *Endocr Rev* 18:26–45. <https://doi.org/10.1210/edrv.18.1.0292>
7. Nugent MA, Iozzo RV (2000) Fibroblast growth factor-2. *Int J Biochem Cell Biol* 32:115–120. [https://doi.org/10.1016/S1357-2725\(99\)00123-5](https://doi.org/10.1016/S1357-2725(99)00123-5)
8. Cross MJ, Claesson-Welsh L (2001) FGF and VEGF function in angiogenesis: signalling pathways, biological responses and therapeutic inhibition. *Trends Pharmacol Sci* 22:201–207. [https://doi.org/10.1016/S0165-6147\(00\)01676-X](https://doi.org/10.1016/S0165-6147(00)01676-X)
9. Dantas Filho AM, Aguiar JL, Rocha LR, Azevedo IM, Ramalho E, Medeiros AC (2007) Effects of the basic fibroblast growth factor and its anti-factor in the healing and collagen maturation of infected skin wound. *Acta Cir Bras* 22:64–71. <https://doi.org/10.1590/S0102-86502007000700013>
10. Makino T, Jinnin M, Muchemwa FC et al (2009) Basic fibroblast growth factor stimulates the proliferation of human dermal fibroblasts via the ERK1/2 and JNK pathways. *Br J Dermatol* 162:717–723. <https://doi.org/10.1111/j.1365-2133.2009.09581.x>
11. Schlessinger J, Plotnikov AN, Ibrahim OA et al (2000) Crystal structure of a ternary FGF-FGFR-heparin complex reveals a dual role for heparin in FGFR binding and dimerization. *Mol Cell* 6:743–750. [https://doi.org/10.1016/S1097-2765\(00\)00073-3](https://doi.org/10.1016/S1097-2765(00)00073-3)
12. Yan D, Chen D, Cool SM et al (2011) Fibroblast growth factor receptor 1 is principally responsible for fibroblast growth factor 2-induced catabolic activities in human articular chondrocytes. *Arthritis Res Ther* 13:R130. <https://doi.org/10.1186/ar3441>
13. Mittermayr R, Antonic V, Hartinger J et al (2012) Extracorporeal shock wave therapy (ESWT) for wound healing: technology, mechanisms, and clinical efficacy. *Wound Repair Regen* 20:456–465. <https://doi.org/10.1111/j.1524-475X.2012.00796.x>
14. Kuo Y-R, Wu W-S, Hsieh Y-L et al (2007) Extracorporeal shock wave enhanced extended skin flap tissue survival via increase of topical blood perfusion and associated with suppression of tissue pro-inflammation. *J Surg Res* 143:385–392. <https://doi.org/10.1016/j.jss.2006.12.552>
15. Schaden W, Thiele R, Köpl C et al (2007) Shock wave therapy for acute and chronic soft tissue wounds: a feasibility study. *J Surg Res* 143:1–12. <https://doi.org/10.1016/j.jss.2007.01.009>
16. Birgin E, Gebhardt C, Hetjens S et al (2018) Extracorporeal shock wave therapy enhances receptor for advanced glycosylated end-product-dependent flap survival and angiogenesis. *Ann Plast Surg*. <https://doi.org/10.1097/SAP.0000000000001279>
17. Goh C (2009) The need for evidence-based aesthetic dermatology practice. *J Cutan Aesthet Surg* 2:65–71. <https://doi.org/10.4103/0974-2077.58518>
18. Soares CD, Borges CF, Sena-Filho M et al (2017) Prognostic significance of cyclooxygenase 2 and phosphorylated Akt1 overexpression in primary nonmetastatic and metastatic cutaneous melanomas. *Melanoma Res* 27:448–456. <https://doi.org/10.1097/CMR.0000000000000368>
19. Knobloch K, Kraemer R (2015) Extracorporeal shock wave therapy (ESWT) for the treatment of cellulite – a current metaanalysis. *Int J Surg* 24:210–217. <https://doi.org/10.1016/J.IJSU.2015.07.644>
20. Zhang X, Yan X, Wang C et al (2014) The dose–effect relationship in extracorporeal shock wave therapy: the optimal parameter for extracorporeal shock wave therapy. *J Surg Res* 186:484–492. <https://doi.org/10.1016/j.jss.2013.08.013>
21. Rosso F, Bonasia DE, Marmotti A et al (2015) Mechanical stimulation (pulsed electromagnetic fields “PEMF” and extracorporeal shock wave therapy “ESWT”) and tendon regeneration: a possible alternative. *Front Aging Neurosci* 7:211. <https://doi.org/10.3389/fnagi.2015.00211>
22. Vetrano M, d’Alessandro F, Torrisi MR et al (2011) Extracorporeal shock wave therapy promotes cell proliferation and collagen synthesis of primary cultured human tenocytes. *Knee Surg Sports Traumatol Arthrosc* 19:2159–2168. <https://doi.org/10.1007/s00167-011-1534-9>
23. Frairia R, Berta L (2011) Biological effects of extracorporeal shock waves on fibroblasts. a review. *Muscles Ligaments Tendons J* 1:138–147
24. Kuo Y-R, Wang C-T, Wang F-S et al (2009) Extracorporeal shock wave treatment modulates skin fibroblast recruitment and leukocyte infiltration for enhancing extended skin-flap survival. *Wound Repair Regen* 17:80–87. <https://doi.org/10.1111/j.1524-475X.2008.00444.x>
25. Wang C-J (2003) An overview of shock wave therapy in musculoskeletal disorders. *Chang Gung Med J* 26:220–232
26. Meirer R, Brunner A, Deibl M et al (2007) Shock wave therapy reduces necrotic flap zones and induces VEGF expression in animal epigastric skin flap model. *J Reconstr Microsurg* 23:231–236. <https://doi.org/10.1055/s-2007-981506>
27. Serizawa F, Ito K, Matsubara M et al (2011) Extracorporeal shock wave therapy induces therapeutic lymphangiogenesis in a rat model of secondary lymphoedema. *Eur J Vasc Endovasc Surg* 42:254–260. <https://doi.org/10.1016/j.ejvs.2011.02.029>
28. Hausdorf J, Sievers B, Schmitt-Sody M et al (2011) Stimulation of bone growth factor synthesis in human osteoblasts and fibroblasts after extracorporeal shock wave application. *Arch Orthop Trauma Surg* 131:303–309. <https://doi.org/10.1007/s00402-010-1166-4>
29. Adatto MA, Adatto-Neilson R, Novak P (2011) Body shaping with acoustic wave therapy AWT(®)/EPAT(®): randomized, controlled study on 14 subjects. *J Cosmet Laser Ther* 13:291–296. <https://doi.org/10.3109/14764172.2011.630089>
30. Knobloch K, Joest B, Vogt PM (2010) Cellulite and extracorporeal shockwave therapy (CelluShock-2009)—a randomized trial. *BMC Womens Health* 10:29. <https://doi.org/10.1186/1472-6874-10-29>
31. Hruza GJ, Dover JS (1996) Laser skin resurfacing. *Arch Dermatol* 132(4):451–455
32. Rostan EF (2005) Laser treatment of photodamaged skin. *Facial Plast Surg* 21(2):99–109
33. Tao L, Wu J, Qian H (2015) Intense pulsed light, near infrared pulsed light, and fractional laser combination therapy for skin rejuvenation in Asian subjects: a prospective multi-center study in China. *Lasers Med Sci* 30(7):1977–1983. <https://doi.org/10.1007/s10103-015-1792-8>