

Lateral epicondylitis

From writer's cramp to power Doppler

Karsten Knobloch

English Translation of original article in German »Epicondylitis humeri radii - Vom "Schreibkrampf" zum Power-Doppler« in *Plastische Chirurgie* 02/2008

On 26th May 1873, Dr F. Runge from Nassau, Germany, published his article entitled "Genesis and treatment of writer's cramp" [1] in the weekly medical journal *Berliner Klinische Wochenschrift*. In that article, Dr Runge wrote: *"In the course of the past year, a few patients with writer's cramp came to my office. The disorder was so well characterised that its detailed description seems all the more gratifying because the views about the nature of this affliction still differ strongly. [...] Right from its onset, the affliction causes excruciating pain which initially affects the forearm and hand and then spreads to the upper arm and even to the shoulder if strain continues. [...] Thorough examination by palpation reveals a small spot at the external condyle of the upper arm, more precisely right where the supinator longus, extensor carpi and digitorum communis insert, which is not only extremely tender but also causes a strong reflex response to pressure. When pressure continues, pain spreads to the hand and upper arm. Apparently, the periosteum of the external humeral condyle is the site of a chronic inflammation. [...] The attachment of the pronator longus, extensor carpi radialis longus and extensor digitorum communis muscles is the site of the chronic inflammation. The alternating contractions of these muscles exert continuous strain on the focus of the inflammation, which the patient attempts to alleviate by fixing the affected site through tonic contraction of individual muscles. Nevertheless, if strain continues the excitation spreads from the locus affectus to other sites in its vicinity; the muscles become hyperaemic."*

This account from 1873 is remarkable if one considers that, as will be discussed later in greater detail, the so-called neovascularisation diagnosed with colour Doppler ultrasound in tennis elbow patients was not described until 2006. Similarly noteworthy are the therapy methods adopted by Dr Runge at the time:

"Therefore, I applied a cauter to the painful site which destroyed the entire skin in an area about the size of a shilling. Subsequent scarring was accompanied by complete elimination of pain in the periosteum, which I assume is attributable to the progressive sclerosing process of the vessels into the depth. I need hardly mention that the patient had to wear an arm sling all the time because immobilisation is a factor that can never be dispensed with in the healing of this affliction. However, immobilisation was only required for a period of six weeks until the cauterised area had completely scarred. As the patient declared to me even one year later, he was and remained completely free of any affliction causing cramping after the cure. Of course, I instructed the patient to refrain from writing during the initial post-treatment period."

From this it follows that Dr Runge was the first doctor to perform local cauterisation by external sclerosing with a one-year follow-up.

Strength measurement with a dynamometer may be useful in the diagnosis of lateral epicondylitis

In addition to pain in the elbow and proximal forearm provoked in many cases during clinical examination by dorsal extension of the wrist against resistance, some patients also complain of tenderness in a skin area on the extensor side of the wrist. Strength measurement with the dynamometer can be useful in the diagnosis of lateral epicondylitis [2]. While in patients with healthy elbows measurements performed with the dynamometer do not reveal any difference in grip strength scores when the elbow is extended with respect to the elbow being positioned in

90 degrees flexion, epicondylitis patients show significant differences in grip strength according to the elbow position. With the elbow in 90 degrees flexion, the grip strength in epicondylitis patients was 29 percent higher than with the elbow joint held in full extension. The recorded strength of the affected arm was around 50 percent of the strength of the unaffected arm with the elbow in extension and 69 percent with the elbow held in 90 degrees flexion. Moreover, there was an 8 percent difference between the extended and the flexed to 90 degrees position in precisely 83 percent between the affected and unaffected extremity.

Modern ultrasound technology has had a vital impact on improved visualisation, especially in the diagnosis of lateral epicondylitis. Conventional grey-scale ultrasound imaging of tendinopathy typically reveals hypoechogenic echo patterns at the insertion of the extensor carpi communis tendon. The following characteristics are frequently found in grey-scale ultrasound imaging [3]:

- calcifications at the tendon attachment of the extensor carpi communis muscle,
- tendon thickening,
- adjacent bone irregularities,
- focal hypoechogenic patterns,
- diffuse heterogeneity.

Colour Doppler ultrasound imaging of lateral epicondylitis patients can reveal increased perfusion in the elbow insertion area [4]. The region exhibiting the pathological increase in blood flow is associated with the pain site. In this neovascularisation region, the capillary vessels have a high density of pain receptors and pain mediators such as substance P and CGRP. Compared to colour Doppler ultrasound, power Doppler sonography enables even better visualisation of vessels with slow blood flow velocity. This is why power Doppler imaging can offer decisive benefits in the visualisation of neovascularisation (Figs. 1, 2).

Combined laser Doppler and spectrophotometry (Oxygen-to-see system from LEA Medizintechnik) enables real-time measurement of the following three microcirculation parameters:

- capillary blood flow as inflow,
- tendon oxygen saturation as a metabolic measure of tenocytes,
- capillary venous outflow as a measure of venous congestion.

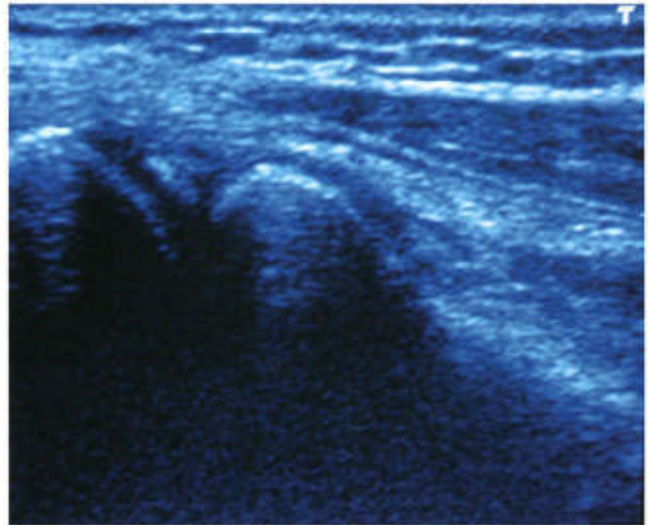


Fig. 1 Conventional grey-scale ultrasound image of elbow with visualisation of epicondyle (left side), inserting tendons and head of radius (central)

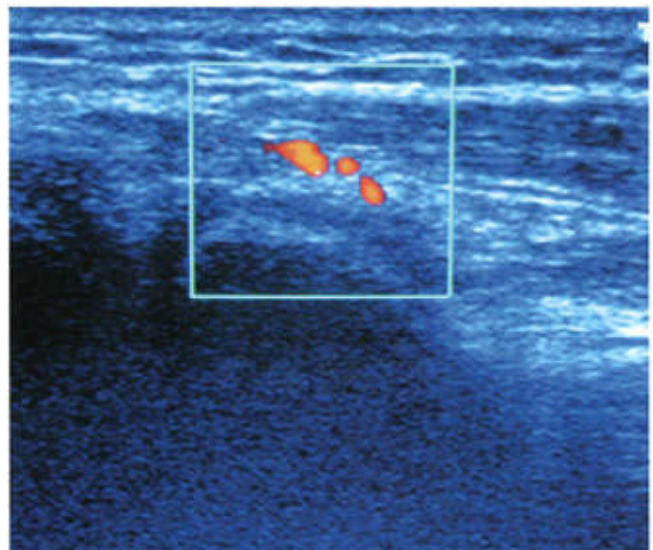


Fig. 2 Power Doppler ultrasound image of elbow affected by epicondylitis with evidence of pathologically increased blood flow during rest (neovascularisation)

In the examination of Achilles tendinopathy, we were able to identify an increase in capillary blood flow by up to 40 percent at the pain site in the Achilles tendon region [5].

Physical therapy: daily eccentric strength training reduces pain

In patients with Achilles tendinopathy, daily eccentric strength training reduces the pathologically increased blood flow at the pain site by 45 percent [6]. Encouraged by reports of successful eccentric strength training in the treatment of Achilles tendon and patellar tendon disorders, we developed an eccentric strength training programme for the upper extremity. Performing the daily exercises at home, patients are required to alternate between pronation and supination against a resistance. They hold a flexible rubber bar (e.g. a green Thera-Band FlexBar) with their arms stretched out horizontally away from the body and bend the rubber bar, rotating their arms into supination and maintaining this position for 2 seconds. Then they move their arms into pronation, again holding this position for 2 seconds. This counts as one repetition, with the patient being required to perform 15 repetitions in one exercise. After a 2-minute break, the patient has to repeat the exercise. Overall, 3 exercises in the morning (each comprising 15 repetitions) and 3 in the evening need to be performed every day over a 12-week period. So far, we have used this training programme with great success in the treatment of lateral epicondylitis, medial epicondylitis, wrist tendinopathy of the flexor carpi ulnaris tendon [7] and De Quervain's disease [8] (Figs. 3, 4).

Epicondylitis patients have a substantially impaired proprioception of the elbow joint [9]. Perception of angular degrees during passive elbow movement is 1.8 degrees in epicondylitis patients, compared to 1.1 degrees in subjects with healthy elbows. On the basis of these findings, we are currently investigating whether vibration training of the upper extremity with an elastic flexible fitness bar (e.g. FlexBar or Propriomed) can be successfully used in a randomised study of epicondylitis patients. Initial interim results suggest that significant pain reduction can be achieved by daily 5-minute vibration training (Figs. 5 to 7).

Botulinum toxin A injections in tennis elbow treatment: no evidence of clear effect so far

The use of botulinum toxin in tennis elbow treatment has been investigated in several randomised controlled studies. A total of 60 epicondylitis patients were randomised to either a one-off treatment with 60 units of botulinum toxin A or placebo [10]. Pain intensity was reduced from 65 ± 15 (VAS 0-100) to 24 ± 22 in the verum group (botox group) and from 66 ± 13 to 44 ± 24 in the placebo group. There was no significant difference between the two groups in terms of the grip strength.



Fig. 3 Eccentric strength training in epicondylitis treatment with flexible hard rubber bar (Thera-Band FlexBar): supination movement with 15 repetitions, 6 times a day for 12 weeks



Fig. 4 Eccentric strength training in epicondylitis treatment with flexible hard rubber bar (Thera-Band FlexBar): pronation alternating with supination, 15 repetitions, 6 times a day for 12 weeks



Fig. 5 Vibration training of upper extremity with Propriomed system




Fig. 6 Vibration training to promote proprioception in epicondylitis patients

Fig. 7 Propriomed bar for proprioceptive training

Finger extension weakness was reported by ten patients in the verum group and six subjects in the placebo group. A multi-centre study [11] of 132 patients investigated the effect of a single injection of botulinum (botulinum toxin A, 0.6 ml NaCl 0.9 % with 60 mouse units) compared to a placebo injection. The injection was administered three to four centimetres distally from the tender lateral epicondyle, without ultrasound guidance. Physiotherapy was interrupted for six weeks. Patients were allowed to use a maximum daily amount of 150 mg of Diclofenac as an analgesic. Two weeks after the injection, pain reduction achieved in the verum group was found to be better than in the placebo group. However, middle finger extensibility was significantly diminished in the verum group, though this phenomenon disappeared after 18 weeks. These findings suggest that botulinum toxin A injections, unlike other injection substances, may have a potential impact on insertional tendinopathy, but there is no evidence so far that they produce a lasting improvement in grip strength. However, it may well be that the type of administered substance, be it cortisone, polidocanol or botulinum toxin A, only plays a minor role and that the key determining factor for the success of the therapy is the power Doppler controlled choice of the ideal injection point. This issue will be discussed in more detail in the following section and could well be investigated in further prospective, randomised studies.

Power Doppler controlled sclerosing therapy can apparently reduce pain and improve grip strength

Following the identification of pathological neovascularisation in the area of the insertion, diagnosed by colour Doppler or power Doppler imaging, targeted sclerosing of these neovessels in the elbow under colour Doppler ultrasound guidance was first described in 2006 [12]. In this pilot study, 11 patients (mean age 46 years), who had been suffering from tennis elbow pain for an average of 23 months, received injections of 2 ml of polidocanol. Colour Doppler imaging revealed that all subjects exhibited structural alterations of tendons and a pathologically increased blood flow at the point of insertion. The subjects in the study were sitting with the affected elbow flexed to 70 to 80 degrees and the forearm pronated. Using a 0.7 mm needle, 2 ml of polidocanol were injected under colour Doppler guidance for targeted sclerosing until the blood flow was found to have ceased. Three months after sclerosing therapy, pain intensity rated on the visual analog scale had significantly reduced from 75 to 47.

Grip strength had increased from 32 to 38 kg. Four subjects complained of strong elbow pain during the first week after the injection. No other side effects were reported in the course of this pilot study.

Encouraged by these results, the same working group around Hakan Alfredson from Umeå in Sweden published a randomised controlled study in April 2008 [13] in which 32 epicondylitis patients (aged between 27 and 66 years) were observed over a period of 12 months. The subjects were randomised to receive either an injection of polidocanol under colour Doppler guidance or colour Doppler coded injection of lidocaine/suprarenin. At the one-year follow-up, both groups had significantly reduced pain scores, but there was no difference between the groups. Grip strength was found to have increased from 37 kg to 47 kg in the polidocanol group and from 43 kg to 48 kg in the lidocaine/adrenalin group. Interestingly, this first comparative randomised study did not reveal any difference between the two groups that would result from the type of injected substance. What seems to matter more in this context is the colour Doppler coded control of the target area for injection (neovascularisation zone) [14].

Topical glyceryl trinitrate therapy: released nitric oxide has an effect on nitric oxide synthases

A randomised controlled study into the effect of topical application of glyceryl trinitrate in 86 lateral epicondylitis patients was published in 2003 [15]. The subjects in this study were randomised to a verum treatment with GTN patches that delivered 1.25 mg of GTN per day or to a control group with placebo patches for a period of 12 weeks. Patients in the GTN group reported reduced elbow pain after two weeks and reduced elbow tenderness after six and twelve weeks.

When applied in the treatment of Achilles tendinopathy, the daily topical application of glyceryl trinitrate for a period of six months confirmed reduced pain intensity and improved function scores in the three-years follow-up [16]. This positive effect seems to result from the impact of the released nitric oxide (NO) on the nitric oxide synthases (NOS) (Table 1). Interestingly, the topical application of glyceryl trinitrate does not lead to an acute increase in blood flow at the Achilles tendon at 2 and 8 mm depth. However, investigations into human Achilles tendon microcirculation have shown that topical NO improves the venous outflow [17]. At present, we recommend to apply two meter doses of GTN spray (e.g. corangin spray) twice daily to the painful site on the elbow for a period of six months.

Shock wave therapy: beneficial, but no consensus on optimum dosage, dosage form and therapy frequency

Extracorporeal shock wave therapy is a procedure frequently used in the treatment of musculoskeletal disorders and tendinopathies. Shock wave application in the treatment of tendon diseases has been investigated in a number of studies, some of them randomised and controlled. In a randomised clinical trial conducted on 50 patients with patellar tendinopathy, for example, pain reduction and functional improvement achieved in the treatment group with shock wave therapy were significantly better than in the control group [18]. However, all published studies have concluded that treatment results may vary with shock wave type (radial or planar), energy dose or therapy frequency (one to three sessions at weekly intervals). Consequently, in the metaanalyses of randomised controlled studies there is at present no clear consensus on the optimum dosage, dosage form and therapy frequency of shock wave therapy. Nevertheless, shock wave application can be used successfully in the treatment of epicondylitis. In fact, in patients who had previously undergone unsuccessful physiotherapy and injection therapy three sessions of shock wave treatment were able to reduce pain intensity rated on the visual analog scale from 6.5 to 2 [19]. We recommend three sessions of concomitant planar shock wave therapy at weekly intervals.

Overall, colour Doppler and power Doppler ultrasound imaging have shown to contribute to the identification of neovascularisation at the pain site. In this context, hybrid procedures may prove useful, such as the combination of power Doppler ultrasound in the operating theatre with targeted electrocoagulation as a minimally invasive surgery option. This combination for operating theatre applications has been described in a recent study on the treatment of patellar tendinopathy [20]. Another pilot study [21] was concerned with the targeted, minimally invasive electrocoagulation treatment for controlled destruction of neovascularisation in Achilles tendinopathy patients. As a result, colour Doppler or power Doppler ultrasound could also be used in the operating theatre during epicondylitis surgery without any difficulties. Intraoperative visualisation might enable targeted, if necessary arthroscopic, denudation of the neovessels, without requiring blood arrest. However, whether this operative hybrid procedure can provide superior clinical success rates remains to be investigated in controlled randomised studies.

Table 1 Up-regulation and down-regulation of different genes of cultivated tendon cells after exposition to NO [22]

Primary function	Gene	Effect on gene regulation
Apoptosis	Immediate early response 3	Up-regulation
	Jun-D	Up-regulation
	COP9 constitutive photomorphogenic homolog subunit 8	Up-regulation
	Growth arrest-specific 2 like 1	Down-regulation
Cell adhesion	Protocadherin Alpha 6	Up-regulation
	Catenin	Down-regulation
Extracellular matrix	Matrix Metalloproteinase 10	Down-regulation
	Collagen type 1	Down-regulation
	Decorin	Down-regulation
	Laminin B2	Down-regulation
	Biglycan	Down-regulation
	Collagen type 3	Down-regulation
	Collagen type 4	Up-regulation
Signal transduction	TNF receptor-associated factor 5	Up-regulation
	Rho GTPase-activating protein 4	Up-regulation
	Interleukin 18 receptor 1	Up-regulation
	IGF-II mRNA-binding protein 3	Up-regulation

Table 2 Current conservative therapy recommendations for lateral epicondylitis

Treatment	Aids	Dose
Eccentric strength training	Green Thera-Band FlexBar	6 exercises per day for 12 weeks, each exercise comprising 15 repetitions of alternating supination and pronation
Topical application of glyceryl trinitrite	Glyceryl trinitrite spray, e.g. corangin N1	2 meter doses twice daily (1 meter dose = 0.4 mg) to the painful site for 6 months
Colour/power Doppler guided injections	1 ampoule of polidocanol 0.25 %	2 ml of titrated polidocanol under colour/power Doppler guidance at intervals of 4 to 6 weeks, 3 to 5 injections
Shock wave therapy	Planar shock wave therapy, e.g. with shock wave system from Storz Medical AG (8274 Tägerwil, Switzerland)	3 sessions at weekly intervals, energy level 0.08 mJ/mm ² , frequency 6 Hz, total dose per session 5699 J

Priv.-Doz. Dr med. Karsten Knobloch
Plastic, Hand and Reconstructive Surgery
Hannover Medical School
Carl-Neuberg-Str. 1
30625 Hannover
Germany
E-mail: kknobi@yahoo.com

Literatur

1. Runge F (1873) Zur Genese und Behandlung des Schreibekrampfes. Berlin Klin Wochenschr 21: 245–248
2. Dorf ER, Chhabra AB, Golish SR, et al (2007) Effect of elbow position on grip strength in the evaluation of lateral epicondylitis. *J Hand Surg [Am]* 32: 882–886
3. Levin D, Nazarian LN, Miller TT, et al (2005) Lateral epicondylitis of the elbow: US findings. *Radiology* 237: 230–234
4. Zeisig E, Ohberg L, Alfredson H (2006) Extensor origin vascularity related to pain in patients with Tennis elbow. *Knee Surg Sports Traumatol Arthrosc* 14: 659–663
5. Knobloch K, Kraemer R, Lichtenberg A, et al (2006) Achilles tendon and paratendon microcirculation in mid-portion and insertional tendinopathy in athletes. *Am J Sports Med* 34: 92–97
6. Knobloch K (2007) Eccentric training in Achilles tendinopathy: is it harmful to tendon microcirculation? *Br J Sports Med* 41: e2
7. Knobloch K, Spies M, Busch KH, Vogt PM (2007) Sclerosing therapy and eccentric training in flexor carpi ulnaris tendinopathy in a tennis player. *Br J Sports Med* 41: 920–921
8. Knobloch K, Gohritz A, Spies M, Vogt PM (2008) Neovascularisation in de Quervain's disease of the wrist: novel combined therapy using sclerosing therapy with polidocanol and eccentric training of the forearms and wrists—a pilot report. *Knee Surg Sports Traumatol Arthrosc* 2008 [May 31, Epub ahead of print]
9. Juul-Kristensen B, Lund H, Hansen K, et al (2008) Poorer elbow proprioception in patients with lateral epicondylitis than in healthy controls: a cross-sectional study. *J Shoulder Elbow Surg* 17 (Suppl 1): 72S–81S
10. Wong SM, Hui AC, Tong PY, et al (2005) Treatment of lateral epicondylitis with botulinum toxin: a randomized, double-blind, placebo-controlled trial. *Ann Intern Med* 143: 793–797
11. Placzek R, Drescher W, Deuretzbacher G, et al (2007) Treatment of chronic radial epicondylitis with botulinum toxin A. A double-blind, placebo-controlled, randomized multicenter study. *J Bone Joint Surg [Am]* 89: 255–260
12. Zeisig E, Ohberg L, Alfredson H (2006) Sclerosing polidocanol injections in chronic painful tennis elbow—promising results in a pilot study. *Knee Surg Sports Traumatol Arthrosc* 14: 1218–1224
13. Zeisig E, Fahlström M, Ohberg L, Alfredson H (2008) Pain relief after intratendinous injections in patients with tennis elbow: results of a randomised study. *Br J Sports Med* 42: 267–271
14. Knobloch K, Hoffmann N, Schiffke B, et al (2008) The injected agent with color Doppler—does it matter in tennis elbow? *Br J Sports Med* [Apr 4, eComment]
15. Paoloni JA, Appleyard RC, Nelson J, Murrell GA (2003) Topical nitric oxide application in the treatment of chronic extensor tendinosis at the elbow: a randomized, double-blinded, placebo-controlled clinical trial. *Am J Sports Med* 31: 915–920
16. Paoloni JA, Murrell GA (2007) Three-year follow-up study of topical glyceryl trinitrate treatment of chronic noninsertional Achilles tendinopathy. *Foot Ankle Int* 28: 1064–1068
17. Knobloch K, Osadnik R, Vogt PM (2008) Acute effects of topical nitroglycerin on Achilles tendon microcirculation. *Br J Sports Med* [im Druck]
18. Wang CJ, Ko JY, Chan YS, et al (2007) Extracorporeal shockwave for chronic patellar tendinopathy. *Am J Sports Med* 35: 972–978
19. Decker T, Kuhne B, Göbel F (2002) Extracorporeal shockwave therapy (ESWT) in epicondylitis humeri radialis. Short-term and intermediate-term results. *Orthopäde* 31: 633–636
20. Willberg L, Sunding K, Forssblad M, Alfredson H (2008) Ultrasound- and Doppler-guided arthroscopic shaving to treat Jumper's knee: a technical note. *Knee Surg Sports Traumatol Arthrosc* 15: 1400–1403.
21. Boesen MI, Torp-Pedersen S, Koenig MJ, et al (2006) Ultrasound guided electrocoagulation in patients with chronic non-insertional Achilles tendinopathy: a pilot study. *Br J Sports Med* 40: 761–766
22. Molloy TJ, de Bock C, Wang Y, Murrell GA (2006) Gene expression changes in SNAP-stimulated and iNOS-transfected tenocytes—expression of extracellular matrix genes and its implications for tendon-healing. *J Orthop Res* 24: 1869–1882

Priv.-Doz. Dr. med. Karsten Knobloch
 Plastische, Hand- und Wiederherstellungschirurgie
 Medizinische Hochschule Hannover
 Carl-Neuberg-Straße 1, 30625 Hannover
 eMail: kknobi@yahoo.com