

Reprint

Perspectives on Modern Orthopaedics

Extracorporeal Shock Wave Therapy in the Treatment of Chronic Tendinopathies

Newsletter Volume 14, Number 4

Extracorporeal Shock Wave Therapy in the Treatment of Chronic Tendinopathies

Andrew Sems, MD

Robert Dimeff, MD

Joseph P. Iannotti, MD, PhD

Dr. Sems is Consultant Surgeon, Department of Orthopaedic Surgery, Mayo Clinic, Rochester, MN. Dr. Dimeff is Medical Director of Sports Medicine, Department of Orthopaedic Surgery, and Vice Chairman, Department of Family Medicine, Cleveland Clinic, Cleveland, OH. Dr. Iannotti is Professor and Chairman, Department of Orthopaedic Surgery, Cleveland Clinic Lerner College of Medicine of Case Western Reserve University.

None of the following authors or the departments with which they are affiliated has received anything of value from or owns stock in a commercial company or institution related directly or indirectly to the subject of this article: Dr. Sems, Dr. Dimeff, and Dr. Iannotti.

Reprint requests: Dr. Iannotti, The Cleveland Clinic Foundation, 9500 Euclid Avenue, Cleveland, OH 44195.

J Am Acad Orthop Surg 2006;14:195-204

Copyright 2006 by the American Academy of Orthopaedic Surgeons.

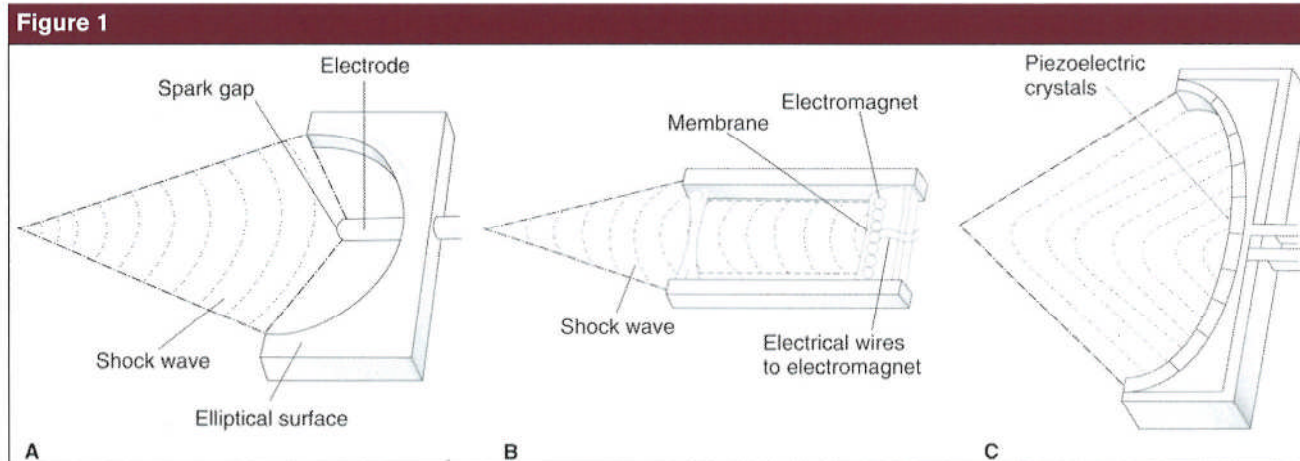
Abstract

Many clinical trials have evaluated the use of extracorporeal shock wave therapy for treating patients with chronic tendinosis of the supraspinatus, lateral epicondylitis, and plantar fasciitis. Although extracorporeal shock wave therapy has been reported to be effective in some trials, in others it was no more effective than placebo. The multiple variables associated with this therapy, such as the amount of energy delivered, the method of focusing the shock waves, frequency and timing of delivery, and whether or not anesthetics are used, makes comparing clinical trials difficult. Calcific tendinosis of the supraspinatus and plantar fasciitis have been successfully managed with extracorporeal shock wave therapy when nonsurgical management has failed. Results have been mixed in the management of lateral epicondylitis, however, and this therapy has not been effective in managing noncalcific tendinosis of the supraspinatus. Extracorporeal shock wave therapy has consistently been more effective with patient feedback, which enables directing the shock waves to the most painful area (clinical focusing), rather than with anatomic or image-guided focusing, which are used to direct the shock wave to an anatomic landmark or structure.

In the past decade, interest has increased in using extracorporeal shock wave therapy (ESWT) to manage chronic tendinopathies that are refractory to other forms of nonsurgical management. Despite the burden of disease that tendon pathology represents and the amount of work that has been performed in the past two decades, much remains to be learned about the etiology, pathophysiology, and management of these tendinopathies. Current nonsurgical protocols are often more an art than a science.

Numerous studies have evaluated

the efficacy of ESWT as a method of managing tendinopathies. Strict comparison of these studies is difficult, however, because of the many variables that define the application parameters of ESWT. These variables include the amount of energy delivered, the method of delivery and focusing, frequency of delivery, and use of anesthesia. In addition, treatment response varies depending on anatomic site, etiology, and severity and chronicity of the condition being treated, as well as in rehabilitation protocols used in conjunction with ESWT. The indica-



Methods of shock wave production. **A**, Electrohydraulic. **B**, Electromagnetic. **C**, Piezoelectric.

tion for the use of ESWT is a chronic tendinopathy, which confuses the issue further because the definition of chronic tendinopathy varies; therefore, patient inclusion criteria differ between studies. The variations relate to the nature and duration of symptoms as well as the associated physical examination findings. As a result, at present no clear consensus exists as to the indications for the use of ESWT. Additional clinical data are required to further establish the ideal treatment protocol for each musculoskeletal condition. Despite these deficiencies, reported results in the literature support a therapeutic benefit and wide safety margin for ESWT for managing chronic tendinopathies of the rotator cuff, lateral epicondyle, and plantar fascia.

Principles of Extracorporeal Shock Wave Therapy

The shock wave used in ESWT is an acoustic pressure disturbance created by the translation of energy via an electrohydraulic, electromagnetic, or piezoelectric device; the wave is transmitted to the patient through either water or a coupling gel. Electrohydraulic shock waves are produced by an electrical discharge across a

spark gap, which causes vaporization of water and a resultant pulse as these bubbles cavitate (Figure 1, A). The pulse is reflected off the elliptical surface of the treatment head, causing a shock wave. Electromagnetically generated shock waves are created via an electromagnet that causes rapid motion of an aluminum foil membrane; that motion compresses the nearby fluid, resulting in the production of a shock wave (Figure 1, B). Piezoelectrically created shock waves are produced when an electrical discharge is applied to several piezoelectric crystals mounted on the inside of the generator (Figure 1, C). The electric discharge causes rapid contraction and expansion of the crystals, resulting in a pressure pulse and subsequent shock wave.

Shock waves have a rapid rise in pressure to 90% of maximum pressure within 10 nsec. This rapid rise is followed by periods of pressure dissipation and of negative pressure before gradually returning to the ambient pressure. The shock wave entering the tissue may be reflected or dissipated, depending on the properties of the tissue. The energy of the shock wave may act through mechanical forces generated directly or indirectly via cavitation.¹

ESWT may be delivered in various energy flux densities, measured

in mJ/mm^2 . Lower-energy flux application (<0.10 to $0.12 \text{ mJ}/\text{mm}^2$) is generally tolerated, with mild to moderate discomfort; high-energy flux applications ($>0.12 \text{ mJ}/\text{mm}^2$) require local or regional anesthesia.² The total amount of energy delivered per session is determined by multiplying the total flux density by the number of shock waves delivered. The multiple combinations of energy flux densities and numbers of shock waves delivered result in differing amounts of total energy delivered to the tissue being treated.

The frequency of shock wave delivery is another variable in ESWT. Frequency, which is measured in hertz, is the number of shock waves delivered per second. ESWT delivery devices are capable of delivering a range of frequencies.

Localizing the delivery of ESWT is another factor that influences the outcome of ESWT and makes comparison of studies difficult. There are three commonly used methods of localization. The first is anatomic focusing, in which the wave is directed at an anatomic location determined by palpation of the structure, such as the insertion of the supraspinatus (supraspinatus tendinosis), the lateral epicondyle (lateral epicondylitis), or the medial process of the calcaneal tuberosity (plantar fasciitis). The

technician administering this treatment must correctly identify and focus the shock wave. In extremely obese patients or patients with altered anatomy (eg, a patient who has had surgery in the region), anatomic focusing may be very difficult.

Image-guided focusing, the second method of localization, may be accomplished via guided ultrasound, fluoroscopy, or computed tomography. Fluoroscopic imaging can direct shock waves at specific osseous or calcified structures; ultrasound is also able to direct shock waves at soft-tissue structures, such as an excessively thickened region of the plantar fascia. These methods of focusing allow delivery of shock waves to a very specific area. Unfortunately, the pain-generating area of pathology may not correlate to these anatomic locations. With plantar fasciitis, the pain is often located at the medial calcaneal tuberosity. Using fluoroscopic guidance to focus on that area allows reliable delivery of treatment to the pathologic tissue.

A third method of localization is clinical focusing, in which the shock waves are directed to the most painful area with the aid of patient feedback. This method is the most reliable at directing the shock waves to the painful region. Clinical focusing allows adjustment of the shock wave direction on a patient-by-patient basis. Because of the need for patient input, no anesthetics can be used with this method, a fact that limits the amount of energy that may be delivered through the shock wave. Higher-energy shock waves are poorly tolerated in the absence of anesthesia. Additionally, performing a placebo-controlled, blinded study using clinical focusing is extremely difficult because of the amount of patient feedback required during treatment. To be effective, shock waves must be administered to the correct anatomic location, and sufficient shock wave energy must be delivered to effect the cellular and sub-cellular histologic, structural, and/or

biochemical changes that will improve the patient's symptoms.

Comparison of studies using different forms of shock wave focusing must be done with the awareness that treatment may have been delivered to different anatomic and pathologic areas. For example, in the case of calcific tendinitis of the supraspinatus, anatomic focusing would direct the shock wave to the insertion of the supraspinatus, image-guided focusing would direct the shock wave to the calcified area, and clinical focusing may focus the energy on yet another area.

Effect on Musculoskeletal Tissue

Application of energy in the form of shock waves affects musculoskeletal tissues in different ways depending on the acoustical impedance of the tissue. The effect of shock waves is most evident at the interface of two materials with different impedance (eg, bone, tendon). When a shock wave encounters a material with different acoustical impedance, a portion of the energy of the wave is transmitted and a portion is reflected. The ratio of the transmitted energy to reflected energy at the interface varies depending on the properties of the tissues involved. The impulse of the high-pressure shock wave on the material interface may cause tension at this interface. Depending on the physical properties of the material, microstructural changes and cracks may occur.

High-energy ESWT has been used in the field of urology for many years to manage nephrolithiasis. The delivery of shock wave energy to the calculus results in its fragmentation and subsequent dissolution. Application of this modality to musculoskeletal conditions was proposed based on a similar theory that the shock wave energy could cause fragmentation of calcific lesions seen in calcific tendinitis. Most published studies of ESWT report using a low-

energy source for managing tendinosis of the supraspinatus, lateral epicondylitis, and plantar fasciitis. Additionally, low-energy ESWT has been used to manage patellar tendinosis, Achilles tendinosis, bone non-union, medial shin syndrome, and osteonecrosis of the hip.

The exact mechanism of action in the treatment of chronic tendinopathies is unknown. It has been hypothesized that the energy delivered via ESWT could result in increased diffusion of cytokines across vessel walls into the pain-generating region, resulting in resolution of the tendinopathy via the stimulation of angiogenesis and the healing response.³ In a recent preclinical study in a rat model, shock waves induced neovascularization at the tendon-bone junction; this was confirmed by posttreatment histologic examination and angiogenesis-related markers. This effect appeared to increase through 8 weeks and persist through 12 weeks after shock wave administration.⁴

Other studies have proposed that pain relief obtained from ESWT may be a result of ESWT-induced nerve fiber degeneration, or possibly of hyperstimulation analgesia.¹ The theory of hyperstimulation analgesia involves stimulation of a brain stem feedback loop involving serotonergic activation via the dorsal horn, which exerts a descending inhibitory control of pain signal transmission. Clinical pain relief after shock wave application may be caused by reduced calcitonin gene-related protein expression in the dorsal root ganglion neurons.⁵ The exact mechanism of action of shock waves in the management of musculoskeletal conditions is unknown.

In a rabbit model, high-energy shock wave application (0.6 mJ/mm²) caused damage to the tendon and paratenon, including an increase in diameter and fibrinoid necrosis, as well as an inflammatory reaction in the peritendinous area. These changes remained 4 weeks after shock

wave application. The lower-energy shock waves did not cause tendon damage.^{6,7} Application of higher-energy shock waves (1.2 mJ/mm²) to a calcified turkey gastrocnemius tendon resulted in significant ($P < 0.05$) impairment of tensile strength, while shock waves of 0.6 mJ/mm² had no effect on tensile strength.⁸ These studies demonstrate that high-energy ESWT has the potential to cause injury to tendon, whereas low-energy applications fail to produce the same injury.

ESWT is often used near articular cartilage. In their study of the effect of shock waves on normal rabbit articular cartilage, Vaterlein et al⁹ reported no changes in the cartilage on macroscopic, radiologic, or histologic examination at 0, 3, 12, and 24 weeks after administration of 2,000 pulses of shock waves at 1.2 mJ/mm². That amount of energy is much higher than is used clinically in any human study. No reports of articular cartilage injury have been reported after ESWT in humans.

Tendinopathies

Tendinopathies can be painful overuse conditions with the potential for causing chronic limitations of activity. Tendinosis is the noninflammatory intratendinous degeneration that causes a decrease in the mechanical properties of the tendon. Tendon tears may occur in the later stages of the disease. These degenerative processes are associated with collagen fiber disorientation, increased cellularity, and angiofibroblastic degeneration. Many of the current treatment regimens are aimed at reducing an inflammatory response through the use of nonsteroidal anti-inflammatory drugs (NSAIDs) and corticosteroid injections. Recent evaluation of the pathophysiology and histology of tendinosis demonstrates that these disorders are degenerative, not inflammatory. There is a conspicuous absence of inflammatory cells and

vascular changes in the areas of maximum involvement, which suggests ineffective vascular supply to the affected region.¹⁰ These findings indicate that alternative treatments may be more effective. In humans, tendinopathies frequently occur in the common extensors of the elbow (eg, lateral epicondylitis) and at the insertion of the supraspinatus (eg, rotator cuff tendinitis).

Tendinosis of the Supraspinatus Tendon

The use of ESWT for managing tendinosis of the shoulder has focused on calcific tendinitis of the supraspinatus. Nonsurgical approaches include activity modification, physical therapy, NSAIDs, corticosteroid injections, and ultrasound. Surgery is done when these modalities fail. Numerous case series, nonrandomized controlled trials, and non-placebo-controlled trials demonstrate clinical improvement with use of both high- and low-energy ESWT in patients with calcific tendinitis of the supraspinatus with dissolution of the calcifications.^{2,11,12} Although limited by their study design, these studies support the use of ESWT in chronic calcific tendinitis of the supraspinatus (Table 1).

ESWT has been compared with other common treatment methods (Table 2). Haake et al¹⁸ studied the method of delivery of ESWT in a controlled, prospective, randomized trial. Fifty patients were randomized to receive two sessions of 4,000 pulses of ESWT at 0.78 mJ/mm² after receiving local anesthesia. The authors used fluoroscopic guidance to focus the shock waves on either the insertion of the supraspinatus or the calcified area of the rotator cuff. The group whose treatment was directed at the calcified area showed statistically significant ($P < 0.05$) improvement in Constant and Murley scores compared with the group whose treatment was focused on the supraspinatus insertion. Charrin and Noel¹⁹ evaluated ultrasonic guidance

to directly deliver low-energy ESWT impulses to manage calcific tendinitis of the rotator cuff in 32 patients. Fifty-five percent of patients improved at 6 months, but results were less favorable than with computed tomography guidance.

Resorption of calcification after ESWT has been found to correlate with improved outcomes. Patients with complete resorption of calcification after ESWT at 0.60 mJ/mm² had significantly better scores than those with either partial resorption ($P = 0.02$) or with no radiomorphologic changes ($P = 0.0003$).²⁰ In their study evaluating radiographic predictors of favorable response to ESWT using magnetic resonance imaging, Maier et al¹² suggested that the absence of contrast enhancement around the deposit is a strong predictive parameter of a positive response to ESWT. The presence and type of calcification seems to be important in determining whether ESWT will be effective. Noncalcific tendinitis of the supraspinatus has not been successfully managed with ESWT (Table 3).

Lateral Epicondylitis

Lateral epicondylitis is a painful condition originating from the common extensor origin at the elbow. The pathogenesis generally consists of abnormalities of the extensor origin, most commonly involving the extensor carpi radialis brevis muscle, with resultant microtears and histologic changes of angiofibroblastic hyperplasia. Treatment strategies have been directed at relieving inflammation through rest, activity modification, NSAIDs, splints, or injections. Corticosteroid injection has been proved to have therapeutic value in the short term, with 1-year results equivalent between injection and placebo. Surgery is considered when these nonsurgical measures fail to provide pain relief.

ESWT has been studied as an alternative to surgery for managing lateral epicondylitis, with favorable

Table 1

Extracorporeal Shock Wave Therapy for Calcific Tendinosis of the Supraspinatus

Author	Study Design and Focusing	ESWT Protocol	Results			Comments
			Pretreatment Constant Score	Posttreatment Constant Score (6 mos)	Pain Relief (%)	
Loew et al ¹³	Randomized parallel case series Fluoroscopic guidance with local anesthetic	Group 1: No treatment	44.5 ± 8.3	47.8 ± 11.4	5	Energy-dependent success, with improved scores and increasing resorption of calcific lesions with more energy
		Group 2: 2,000 pulses at 0.1 mJ/mm ²	39.4 ± 11.2	51.6 ± 20.1	30	
		Group 3: 2,000 pulses at 0.3 mJ/mm ²	39.0 ± 11.8	63.7 ± 14.6	60	
		Group 4: Two sessions of 2,000 pulses at 0.3 mJ/mm ²	43.5 ± 13.1	68.5 ± 13.1	70	
Cosentino et al ¹⁴	Single-blind, randomized, placebo-controlled Sonographic focusing at calcified lesion	Group 1: Four sessions of 1,200 pulses at 0.00 mJ/mm ²	48	50	76 (6 mos)	Significant (<i>P</i> < 0.001) improvement in ESWT group Significantly (<i>P</i> < 0.001) more calcific resorption in ESWT group than in control group (71% complete or partial versus 0%)
		Group 2: Four sessions of 1,200 pulses at 0.28 mJ/mm ²	45	71	44 (6 mos)	
Gerdesmeyer et al ¹⁵	Double-blind, randomized, placebo-controlled trial Fluoroscopic focusing on calcific lesions	Group 1: Sham treatment	64.2	77.9 (12 mos)		High-energy ESWT had improved results compared with low-energy ESWT. Both were better than placebo
		Group 2: 1,500 pulses at 0.32 mJ/mm ²	60	91.6 (12 mos)		
		Group 3: 6,000 pulses at 0.08 mJ/mm ²	62.7	80.4 (12 mos)		

ESWT = extracorporeal shock wave therapy

results. Several nonrandomized studies and case series have been published, generally with improved symptoms and grip strength as a result of ESWT (Table 4).

Perlick et al²⁶ compared ESWT (two sessions of 1,000 impulses of 0.23 mJ/mm²) with surgical treatment consisting of partial resection of the lateral epicondyle and extensor origin in the affected area. Using the Roles and Maudsley pain score, 73% of patients in the surgical group had good or excellent results, compared with 43% in the ESWT group. Crowther et al²⁷ published a prospective randomized controlled study in-

volving 73 patients who received either corticosteroid injection or ESWT. Patients in the injection group received 20 mg of triamcinolone with 1.5 mL of 1% lidocaine. Those in the ESWT group received three sessions of 2,000 low-energy shock waves (<0.10 mJ/mm²) per session under ultrasound guidance with no anesthesia. In the ESWT group, 48 of 51 patients completed the protocol, compared with 25 of 42 in the injection group. At 3 months, pain relief as measured on a visual analog scale (VAS; range, 1-100) decreased from 67 to 12 in the injection group, and from 61 to 31 in the ESWT

group. However, the high rate of refusal in the injection group introduced a notable selection bias.

The amount of pain relief among the patients who received ESWT after failure of corticosteroid injection was consistently higher than the pain relief in patients who had ESWT without prior injections. In trials by Rompe et al²³ and Decker et al,²⁸ 92% and 100% of patients, respectively, had been previously injected with corticosteroids for lateral epicondylitis. These studies had long-term failure rates of 10% and 15%, respectively. In a study with no prior attempts at corticosteroid in-

Table 2

Extracorporeal Shock Wave Therapy Compared With Other Treatments

Study	Study Design and Focusing	ESWT Protocol		Results		Comments
				Pretreatment Constant Score	Posttreatment Constant Score (12 mos)	
Haake et al ¹⁶	Prospective, randomized, single-blind comparison with 6 × 0.5 Gy x-ray	ESWT group: 2,000 pulses at 0.33 mJ/mm ² x-ray group: 6 × 0.5 Gy with cobalt 60 gamma rays (30 pts randomized to either group)		50.1	97.8	No statistically significant differences between the groups
				47.6	87.4	
Rompe et al ²	Prospective quasirandomized comparison with surgical extirpation Fluoroscopic guidance focused on calcification	Surgery group (29 pts): Surgical excision and curettage of calcific lesion	Homogenous calcifications	18.0 ± 3.4	32 ± 4.1	No significant difference at 1 year, but ESWT had improvement at 2 years Surgery was better with homogenous calcifications, and both groups with inhomogenous calcifications were equal
			Inhomogenous calcifications	17.4 ± 4.7	33.1 ± 3.9	
		ESWT group (50 pts): 3,000 pulses at 0.6 mJ/mm ²	Homogenous calcifications	18.7 ± 3.2	26.7 ± 3.6	
			Inhomogenous calcifications	19.2 ± 4.8	31.9 ± 4.7	
Pan et al ¹⁷	Randomized controlled trial Clinical focusing with ultrasonic guidance to most painful area	ESWT group (33 shoulders): Two sessions of 2,000 pulses at 0.26-0.32 mJ/mm ² TENS group (30 shoulders): Three sessions weekly for 4 weeks		63.8 ± 14.2	92.1	ESWT is more effective than TENS
				65.7 ± 15.8	77.5	

ESWT = extracorporeal shock wave therapy, TENS = transcutaneous electric nerve stimulation

jection, however, the failure rate was 40% at 3 months.²⁷ The higher rate of failure in patients who have not previously received injection indicates that failure of corticosteroid injection may be a useful factor in selecting patients for ESWT.

There is insufficient evidence in the literature to make a final deter-

mination on the role of ESWT in the management of lateral epicondylitis. Although Rompe et al²³ reported that three treatments of 1,000 impulses at 0.08 mJ/mm² without anesthesia using anatomic localization is effective in providing notable pain relief, two other studies^{24,25} indicated that similar treatment proto-

cols of 1,500 to 2,000 low-energy impulses with or without local anesthesia are no more effective than placebo. This suggests that anatomic localization may not be an adequate method for determining the optimal site of application. Failure of corticosteroid injection may be an important and positive predic-

Table 3

Extracorporeal Shock Wave Therapy for Noncalcific Tendinosis of the Supraspinatus

Study	Study Design and Focusing	ESWT Protocol		Results			Comments
				Constant Score			
				Pretreatment	Posttreatment (12 wks)	Posttreatment (6 wks)	
Schmitt et al ²¹	Prospective, randomized, placebo-controlled Ultrasound to supraspinatus insertion with local anesthetic	Three sessions of 2,000 pulses at 0.11 mJ/mm ²	Sham treatment	42.2 ± 13	64.2 ± 25.2	64.4 ± 32.7	No benefit from ESWT
			ESWT	40.7 ± 13.3	60.9 ± 29.6	66.5 ± 37.9	
				Shoulder Pain and Disability Index			
				Pretreatment	Posttreatment (1 mo)	Posttreatment (6 mos)	
Speed et al ²²	Prospective, randomized, double-blind, placebo-controlled Localization followed by clinical focusing to maximal tenderness	Three sessions of 1,500 pulses at 0.12 mJ/mm ²	Sham treatment	59.5 ± 16.1	58.5 ± 19.7	34.9 ± 31.7	No benefit from ESWT
			ESWT	53.6 ± 20.2	48.7 ± 21.0	24.1 ± 22.9	

ESWT = extracorporeal shock wave therapy

tive factor in determining a favorable response to ESWT. Further studies are required to answer these questions.

Plantar Fasciitis

Plantar fasciitis, which affects approximately 10% of the US population over the duration of a lifetime, is characterized by pain localized at the origin of the plantar fascia on the calcaneus.²⁹ This pain is worse in the morning and after prolonged periods of non-use, and it is exacerbated by stretching of the plantar fascia. The pathogenesis is unclear, but the condition may be a result of repetitive overloading causing microtears and degeneration. Treatment protocols for plantar fasciitis include combinations of rest, stretching, NSAIDs, corticosteroid injections, and orthotics or casting. Patients refractory to nonsurgical management are occasionally offered surgical in-

tervention consisting of varying degrees of plantar fascial release.

Several authors have suggested using ESWT to manage plantar fasciitis.^{30,31} Prospective, randomized, placebo-controlled trials of ESWT for treating plantar fasciitis have shown both improvement and no change compared with the placebo group.³² Rompe et al³³ conducted a prospective, randomized, placebo-controlled trial of patients with chronic plantar fasciitis who had failed nonsurgical therapy for at least 6 months. The authors compared three sessions of 1,000 pulses of ESWT at 0.08 mJ/mm² under fluoroscopic guidance without anesthesia with three sessions of 10 pulses. The treatment group showed statistically significant ($P < 0.0001$) improvement at 6 months as measured by the Roles and Maudsley pain score. Similar results were reported in one other prospective trial using ESWT

for managing plantar fasciitis.³⁴ One prospective, randomized, placebo-controlled trial of the running athlete with chronic plantar fasciitis demonstrates benefit with clinically focused ESWT application without anesthesia.³⁵ All of these studies used image guidance (fluoroscopic or ultrasonic), and none used any form of anesthesia. Image guidance was used to direct the shock wave to the tip of the calcaneal spur, followed by clinical focusing of the shock wave to the area of maximal pain.

Ogden et al³⁶ published the largest prospective, randomized, placebo-controlled series to date of ESWT in the treatment of plantar fasciitis (302 patients). This study is unique in that it used high-energy shock waves, necessitating regional ankle block anesthesia on all patients, allowing theoretically superior blinding of the patients to the treatment. To be considered success-

Table 4
Extracorporeal Shock Wave Therapy for Lateral Epicondylitis

Study	Study Design and Focusing	ESWT protocol	Results		Comments
			Excellent or Good Roles and Maudsley Outcome		
Rompe et al ²³	Prospective, randomized, placebo-controlled Anatomic guidance at lateral epicondyle	Group 1: 3,000 pulses at 0.08 mJ/mm ² Group 2: 30 pulses at 0.08 mJ/mm ²	24 wks		Treatment group had decrease in pain on VAS and increase in grip strength compared with sham group
			24/50	3/50	
Haake et al ²⁴	Prospective, randomized, placebo-controlled, double-blind Ultrasonic guidance at muscle insertion at lateral epicondyle with local anesthetic	Group 1: Shielded shock wave treatment (sham) Group 2: Three sessions of 2,000 pulses at 0.07-0.09 mJ/mm ²	12 mos		No difference in outcome between groups. Side effects in treatment group included three syncopal episodes and four migraine headaches. None in control group
			66/101	69/105	
Speed et al ²⁵	Prospective, randomized, placebo-controlled, double-blind Ultrasonic guidance to region of interest followed by clinical focusing to most painful area (no anesthetic)	Group 1: Sham treatment Group 2: 1,500 pulses at 0.12/0.18 mJ/mm ²	VAS Pain Score		No added effect of ESWT over placebo Short follow-up Higher-energy shock waves used without anesthetic brings into question accuracy of delivery of therapy
			Pretreatment	Posttreatment (3 mos)	
			67.2	51.5	
			73.4	47.9	

ESWT = extracorporeal shock wave therapy, VAS = visual analog scale

fully treated, the patient was required to meet four criteria: (1) 50% improvement in pain testing with a dolorimeter, (2) 50% improvement over pretreatment VAS pain score, (3) improvement in distance and time walked without pain, and (4) no use of pain medication. Using these criteria, the authors reported that 56% more patients who received treatment had successful results, compared with those in the placebo group. Because of the large difference in the amount of energy delivered through this treatment compared with low-energy shock wave therapy, however, it is not possible to

compare this trial with the remainder of the literature.

In a large trial by Buchbinder et al,³⁷ in which 160 patients completed the treatment protocol, there was no statistically significant difference in any outcome measured between the ESWT and placebo groups. This study was very similar to that of Rompe et al³³ in regard to the amount and energy of shock waves delivered and the time between treatments. The patients in the two trials also had similar mean duration of symptoms, although the study by Buchbinder included patients experiencing symptoms for as little as 8

weeks, whereas Rompe's minimum was 6 months. The trial of Buchbinder et al³⁷ included patients with plantar heel pain and ultrasonic evidence of plantar fascial thickening. Rompe et al³³ required pain at the insertion of the plantar fascia on the medial calcaneal tuberosity. These patient populations were not necessarily the same. Although both studies used image guidance for the localization technique, the shock waves were focused on different areas. Rompe et al³³ focused their shock waves on the tip of the calcaneal spur followed by clinical focusing, while Buchbinder used ultrasound to focus

the shock waves on the thickest part of the plantar fascia. This difference may be several millimeters, resulting in delivery of shock waves to two very different areas. Maier et al³⁸ reported that a pretherapeutic finding of calcaneal bone marrow edema on magnetic resonance imaging was a good predictor of successful outcomes with ESWT. There was no correlation, however, of thickness of the plantar aponeurosis, soft-tissue signal changes, or soft-tissue contrast uptake to clinical outcomes. This may explain the differences in outcomes in the Rompe and Buchbinder trials. Therefore, because the Buchbinder trial focused on the thickest part of the plantar fascia, it is understandable that the ESWT treatments were not as effective as the treatment aimed at the calcaneal spur.

Although the study of Buchbinder et al³⁷ contradicts the remainder of the literature regarding ESWT in the management of chronic plantar fasciitis, concerns regarding the focusing of shock waves in that trial are difficult to overlook. Based on the preponderance of well-designed studies showing favorable results, it seems that ESWT is an effective modality for managing chronic plantar fasciitis in patients who have failed nonsurgical treatment. Treatment should be directed at the tip of the calcaneal spur or by clinical focusing on the most painful area.

Other Tendinoses

Patellar and Achilles tendinopathies have been less well studied than the three tendinopathies already discussed. Peers et al³⁹ conducted the only study to date that retrospectively compares ESWT with patellar tenotomy and resection of degenerative tissue in patients with patellar tendinosis. The patients presented with symptoms that persisted for at least 6 months despite nonsurgical treatment. Both groups showed improvement after treatment, and no significant differences were noted in the Victorian In-

stitute of Sport Assessment or VAS at 6- and 24-month follow-ups.

Achilles tendinosis was evaluated in a study comparing 2,000 pulses of ESWT at 0.23 mJ/mm² with surgical treatment.⁴⁰ Good and excellent results were seen in 69% and satisfactory results in 15% of the surgical group at 1-year follow-up, compared with good and excellent results in 29% and satisfactory results in 43% of the ESWT group. Because of the paucity of information, no definitive conclusions regarding the indications or expected outcome of ESWT for either patellar or Achilles tendinosis can be made at this time.

Summary

ESWT is a promising method of managing chronic tendinopathies. Alone or in conjunction with other treatment modalities, ESWT may provide pain relief and improved function in many patients who have failed other treatment. Calcific tendinitis of the supraspinatus has been managed effectively with ESWT with minimal side effects. Treatment of noncalcific tendinitis of the supraspinatus by ESWT is no more effective than placebo, however, as shown in two well-designed prospective, randomized, controlled studies, and it cannot be recommended at this time.^{21,22} The evidence is inconclusive as to the effectiveness of ESWT for managing lateral epicondylitis, but it seems to be effective with clinical focusing in patients with chronic disease who are treated with appropriate energy levels. Several studies have indicated that plantar fasciitis responds to ESWT.

Shock wave therapy is noninvasive, well-tolerated, and relatively inexpensive compared with surgical treatment.²⁷ Because of the multiple variables inherent in ESWT treatment protocols, strict comparisons of published results are problematic. However, there is sufficient information to conclude that ESWT is an

appropriate treatment in the right circumstances, such as for calcific tendinosis and plantar fasciitis that have failed nonsurgical management. Further investigation of ESWT in the treatment of chronic tendinopathies is warranted and recommended.

References

Evidence-based Medicine: Evidence-based studies are not in the following references: 15, 16, 21, 22, 24, 25, 27, 32, 34, 35, and 37.

Citation numbers printed in **bold type** indicate references published within the past 5 years.

1. Ogden JA, Toth-Kischkat A, Schultheiss R: Principles of shock wave therapy. *Clin Orthop* 2001;387:8-17.
2. Rompe JD, Zoellner J, Nafe B: Shock wave therapy versus conventional surgery in the treatment of calcifying tendinitis of the shoulder. *Clin Orthop* 2001;387:72-82.
3. Chen YJ, Wang CJ, Yang KD, et al: Extracorporeal shock waves promote healing of collagenase-induced Achilles tendinitis and increase TGF-beta1 and IGF-I expression. *J Orthop Res* 2004;22:854-861.
4. Takahashi N, Wada Y, Ohtori S, Saisu T, Moriya H: Application of shock waves to rat skin decreases calcitonin gene-related peptide immunoreactivity in dorsal root ganglion neurons. *Auton Neurosci* 2003;107:81-84.
5. Wang CJ, Wang FS, Yang KD, et al: Shock wave therapy induces neovascularization at the tendon-bone junction: A study in rabbits. *J Orthop Res* 2003;21:984-989.
6. Maier M, Tischer T, Milz S, et al: Dose-related effects of extracorporeal shock waves on rabbit quadriceps tendon integrity. *Arch Orthop Trauma Surg* 2002;122:436-441.
7. Rompe JD, Kirkpatrick CJ, Kullmer K, Schwitalle M, Kruschek O: Dose-related effects of shock waves on rabbit tendo Achilles: A sonographic and histological study. *J Bone Joint Surg Br* 1998;80:546-552.
8. Maier M, Saisu T, Beckmann J, et al: Impaired tensile strength after shock-wave application in an animal model of tendon calcification. *Ultrasound Med Biol* 2001;27:665-671.
9. Vaterlein N, Lussenhop S, Hahn M, Delling G, Meiss AL: The effect of ex-

- tracorporeal shock waves on joint cartilage: An in vivo study in rabbits. *Arch Orthop Trauma Surg* 2000;120:403-406.
10. Kraushaar BS, Nirschl RP: Tendinosis of the elbow (tennis elbow): Clinical features and findings of histological, immunohistochemical, and electron microscopy studies. *J Bone Joint Surg Am* 1999;81:259-278.
 11. Loew M, Jurgowski W, Mau HC, Thomsen M: Treatment of calcifying tendinitis of rotator cuff by extracorporeal shock waves: A preliminary report. *J Shoulder Elbow Surg* 1995;4:101-106.
 12. Maier M, Stabler A, Lienemann A, et al: Shockwave application in calcifying tendinitis of the shoulder—prediction of outcome by imaging. *Arch Orthop Trauma Surg* 2000;120:493-498.
 13. Loew M, Daecke W, Kusnierczak D, Rahmanzadeh M, Ewerbeck V: Shock-wave therapy is effective for chronic calcifying tendinitis of the shoulder. *J Bone Joint Surg Br* 1999;81:863-867.
 14. Cosentino R, De Stefano R, Selvi E, et al: Extracorporeal shock wave therapy for chronic calcific tendinitis of the shoulder: Single blind study. *Ann Rheum Dis* 2003;62:248-250.
 15. Gerdesmeyer L, Wagenpfeil S, Haake M, et al: Extracorporeal shock wave therapy for the treatment of chronic calcifying tendonitis of the rotator cuff: A randomized controlled trial. *JAMA* 2003;290:2573-2580.
 16. Haake M, Sattler A, Gross MW, Schmitt J, Hildebrandt R, Muller HH: Comparison of extracorporeal shock-wave therapy (ESWT) with roentgen irradiation in supraspinatus tendon syndrome: A prospective randomized single-blind parallel group comparison [German]. *Z Orthop Ihre Grenzgeb* 2001;139:397-402.
 17. Pan PJ, Chou CL, Chiou HJ, Ma HL, Lee HC, Chan RC: Extracorporeal shock wave therapy for chronic calcific tendinitis of the shoulders: A functional and sonographic study. *Arch Phys Med Rehabil* 2003;84:988-993.
 18. Haake M, Deike B, Thon A, Schmitt J: Exact focusing of extracorporeal shock wave therapy for calcifying tendinopathy. *Clin Orthop* 2002;397:323-331.
 19. Charrin JE, Noel ER: Shockwave therapy under ultrasonographic guidance in rotator cuff calcific tendinitis. *Joint Bone Spine* 2001;68:241-244.
 20. Rompe JD, Zollner J, Nafe B, Freitag C: Significance of calcium deposit elimination in tendinosis calcarea of the shoulder [German]. *Z Orthop Ihre Grenzgeb* 2000;138:335-339.
 21. Schmitt J, Haake M, Tosch A, Hildebrand R, Deike B, Griss P: Low-energy extracorporeal shock-wave treatment (ESWT) for tendinitis of the supraspinatus: A prospective, randomised study. *J Bone Joint Surg Br* 2001;83:873-876.
 22. Speed CA, Richards C, Nichols D, et al: Extracorporeal shock-wave therapy for tendonitis of the rotator cuff: A double-blind, randomised, controlled trial. *J Bone Joint Surg Br* 2002;84:509-512.
 23. Rompe JD, Hopf C, Kullmer K, Heine J, Burger R: Analgesic effect of extracorporeal shock-wave therapy on chronic tennis elbow. *J Bone Joint Surg Br* 1996;78:233-237.
 24. Haake M, Konig IR, Decker T, Riedel C, Buch M, Muller HH: Extracorporeal Shock Wave Therapy Clinical Trial Group: Extracorporeal shock wave therapy in the treatment of lateral epicondylitis: A randomized multicenter trial. *J Bone Joint Surg Am* 2002;84:1982-1991.
 25. Speed CA, Nichols D, Richards C, et al: Extracorporeal shock wave therapy for lateral epicondylitis—a double blind randomised controlled trial. *J Orthop Res* 2002;20:895-898.
 26. Perlick L, Gassel F, Zander D, Schmitt O, Wallny T: Comparison of results of medium energy ESWT and Mittelmeier surgical therapy in therapy refractory epicondylitis humeri radialis [German]. *Z Orthop Ihre Grenzgeb* 1999;137:316-321.
 27. Crowther MA, Bannister GC, Huma H, Rooker GD: A prospective, randomised study to compare extracorporeal shock-wave therapy and injection of steroid for the treatment of tennis elbow. *J Bone Joint Surg Br* 2002;84:678-679.
 28. Decker T, Kuhne B, Gobel F: Extracorporeal shockwave therapy (ESWT) in epicondylitis humeri radialis: Short-term and intermediate-term results [German]. *Orthopade* 2002;31:633-636.
 29. Crawford F, Atkins D, Edwards J: Interventions for treating plantar heel pain. *Cochrane Database Syst Rev* 2000;3:CD000416.
 30. Ogden JA, Alvarez RG, Marlow M: Shockwave therapy for chronic proximal plantar fasciitis: A meta-analysis. *Foot Ankle Int* 2002;23:301-308.
 31. Rajkumar P, Schmitgen GF: Shock waves do more than just crush stones: Extracorporeal shock wave therapy in plantar fasciitis. *Int J Clin Pract* 2002;56:735-737.
 32. Speed CA, Nichols D, Wies J, et al: Extracorporeal shock wave therapy for plantar fasciitis: A double blind randomised controlled trial. *J Orthop Res* 2003;21:937-940.
 33. Rompe JD, Schoellner C, Nafe B: Evaluation of low-energy extracorporeal shock-wave application for treatment of chronic plantar fasciitis. *J Bone Joint Surg Am* 2002;84:335-341.
 34. Rompe JD, Hopf C, Nafe B, Burger R: Low-energy extracorporeal shock wave therapy for painful heel: A prospective controlled single-blind study. *Arch Orthop Trauma Surg* 1996;115:75-79.
 35. Rompe JD, Decking J, Schoellner C, Nafe B: Shock wave application for chronic plantar fasciitis in running athletes: A prospective, randomized, placebo-controlled trial. *Am J Sports Med* 2003;31:268-275.
 36. Ogden JA, Alvarez R, Levitt R, Cross GL, Marlow M: Shock wave therapy for chronic proximal plantar fasciitis. *Clin Orthop* 2001;387:47-59.
 37. Buchbinder R, Ptasznik R, Gordon J, Buchanan J, Prabakaran V, Forbes A: Ultrasound-guided extracorporeal shock wave therapy for plantar fasciitis: A randomized controlled trial. *JAMA* 2002;288:1364-1372.
 38. Maier M, Steinborn M, Schmitz C, et al: Extracorporeal shock wave application for chronic plantar fasciitis associated with heel spurs: Prediction of outcome by magnetic resonance imaging. *J Rheumatol* 2000;27:2455-2462.
 39. Peers KH, Lysens RJ, Brys P, Bellemans J: Cross-sectional outcome analysis of athletes with chronic patellar tendinopathy treated surgically and by extracorporeal shock wave therapy. *Clin J Sport Med* 2003;13:79-83.
 40. Perlick L, Schiffmann R, Kraft CN, Wallny T, Diedrich O: Extracorporeal shock wave treatment of the Achilles tendinitis: Experimental and preliminary clinical results [German]. *Z Orthop Ihre Grenzgeb* 2002;140:275-280.