



Newsletter

MAY 2008
VOLUME 4, ISSUE 1

Editorial · Editorial comments



Heinz Kuderna, M.D.

*Honorary President
em. Dozent Medical University
em. Medical Director Trauma Center Meidling
Medical Chief Viennese Red Cross
Vienna, Austria*

Chief Editor

• **Paulo Roberto Dias dos Santos, MD**
(Brazil) - prds@uol.com.br

Associate Editor

• **Ching-Jen Wang, MD** (Taiwan)
w281211@adm.cgmh.org.tw

Editorial Board

- **Ana Claudia Souza, MD** (Brazil)
anaclaudia@cortrel.com.br
- **Carlos Leal, MD** (Columbia)
leal@owc.com.co
- **Heinz Kuderna, MD** (Austria)
kuderna-unfallchir.wien@aon.at
- **Helmut Neuland, MD** (Germany)
dr.h.g.neuland@gmx.de
- **Kimberly Eickmeier, MD** (USA)
Keickmeier@christieclinic.com
- **Leonardo Jaime Guiloff Waissbluth, MD** (Chile) - lguiloff@davila.ch
- **Ludger Gerdsmeyer, MD** (Germany)
gerdesmeyer@aol.com
- **Matthias Buch, MD** (Germany)
matthiasbuch@aol.com
- **Richard Thiele, MD** (Germany)
harthi@t-online.de
- **Robert Gordon, MD** (Canada)
gordon@skockwavedoc.com
- **Sergio Russo, MD** (Italy)
serghiey@hotmail.com
- **Vinzenz Auersperg, MD** (Austria)
vinzenz.auersperg@akh.linz.at
- **Weil Lowell Jr, MD** (USA)
lweiljr@weil4feet.com
- **Wolfgang Schaden, MD** (Austria)
med.eswt.schaden@aon.at

Veterinary Committee

- **Scott Mc Clure, DVM** (USA)
mccclures@iastate.edu
- **Ana Liz Garcia Alves, DVM** (Brazil)
anaalves@fmvz.unesp.br
- **Ana Cristina Bassit, DVM** (Brazil)
anabassit@uol.com.br

Editorial Office

Avenida Pacaembú, 1024
CEP 01234-000 - São Paulo - Brazil
Fone: 55-11-3825-8699
E-mail : prds@uol.com.br

website: www.ismst.com

The use of shockwaves to crush uric concretions instead of removing them by surgical procedures has become a generally recognized tool in the hand of urologist in the 8th decade of the last century - less than thirty years ago! The effect to bony structures first has been recognized as an awkward side effect of this treatment and has become in at first timid use for the treatment of delayed fracture healing not even twenty years ago, but with the very quickly recognized side effect to reduce also the concomitant chronic pain. In comparison to other physical methods and even to many surgical methods shockwave treatment in general is an extraordinarily young procedure. This fact always should be kept in mind expecting strong rules for well defined indications and a standardisation of the treatment in those indications with the assessment by the means of evidence based medicine. It was painful to learn that most of the clinical trials performed with the common scientific approach failed to prove the efficacy of shockwave treatment by statistic means without any doubt. The results of different clinical trials for the same indications have been very contradictory. But should this fact really take wonder? Up to now we don't have the last answer to the question, how shockwaves are effecting living tissue. How should it be possible to define the proper appliance in defined indications under these circumstances?

Nevertheless the experimental work has brought a fascinating progress in the last years by a change of mind on principle. In the last years of the last century the shockwave effect to the tissue was regarded as a kind of new trauma similar the demolition of the uric concretions, initiating somehow again the healing process. The interpretation of the concomitant pain release has been pure speculation as for example the input gate control theory. But then we got aware of the improvement of soft tissue condition also

outside the focus for example in chronically infected bony non unions. We got aware of the effects of radial shockwave, transferring only small energy amounts to the tissue as physically possible. We have learned that it is not the physical damage, needing a high energy level, but a very subtle stimulus to the normal regeneration process by the improvement of blood supply, by increase of growth factors, stimulation and differentiation of stem cells, needing much less energy for an optimal effect. than a „trauma“ dosis. This view opened chances for shockwave treatment indications we never have taken in consideration before. Therefore former indications and quality standards of shockwave treatment had to be revised.

It is the merit of the ISMST President 2008, Roland Hamisultane, to initiate a consensus paper of experts concerning the actual indications of ESWT. You can find this consensus paper in the in hand issue of the ISMST Newsletter. It may be a basis for recommendations to patients as well as for negotiations with cost bearers and last not least for your guidance in legal conflicts.

Nevertheless the use of this tool does not mean that shockwave treatment indications may be delivered by other users than doctors. I hope You will understand this recommendation as long as we are far away of understanding the mechanism of ESWT effects to the living tissue in total. The application may be done by medical personnel as well but also under supervision of a doctor who is familiar with the indications.

The publication of the consensus paper underlines also the necessity for the ISMST of having a print matter like this ISMST Newsletter and I want to thank once more the founder and chief editor Paulo Roberto Dias dos Santos for his efforts to the benefit for all of us.

Inside this Issue	
Editorial comments	1
Consensus statement Recommendations for the use of extracorporeal shockwave technology in medical indications	2
Extracorporeal Shockwave in Hip Necrosis	3
When is the right time for ESWT?	
Influence of ESWT on Ischemia Induced Tissue Necrosis and its Correlation with Application Time	6
Mid-portion Achilles tendinopathy - What role is there for shock wave treatment?	9
Extracorporeal Shock Waves Influences Migration, Proliferation and Growth of Human Mesenchymal Stem Cells	13
Improvement of Active Ankle Joint Dorsiflexion by the Use of Extracorporeal Pulse Activation Therapy (EPAT) in Patients with Chronic Achilles Tendinosis: A New Approach	17

Consensus statement

Recommendations for the use of extracorporeal shockwave technology in medical indications

Introduction

Building on the experience gained over the past 15 years, the scientific board of the ISMST and experts from National Shockwave Societies around the world, have put together a set of recommendations for the use of shockwave therapy.

Purposefully the experts did not apply Cochrane standards for the assessment of the level of evidence. The most recent meta-analyses published by Cochrane shows "platinum evidence" that shockwave treatment has little or no effect at all. But Cochrane researchers simply cannot ignore the results of several well-designed studies from the past which failed to show any efficacy of ESWT for various disorders. By analysing those studies it could be shown that inclusion criteria, treatment parameters or other conditions are afflicted with systemic biases which turn the results of the studies completely into the opposite. Therefore, as long as the situation is so incoherent the idea of a ranking due to the level of evidence is not reasonable or feasible.

Prerequisites

In order to prevent improper treatment the following are prerequisites for administering the technology:

In addition to a clinical examination, radiological imaging, neurological and/or laboratory-diagnostic tests may be necessary to corroborate the diagnosis.

Only a qualified (certified by National or International Societies) physician may use shockwave therapy to treat pathologies, which have been determined by diagnostic testing.

For the treatment of bone ailments, a high-energy, focused shockwave with positioning technology is to be used. To treat superficial soft tissue conditions, devices with or without focusing technology may be utilized; close attention must be paid to the depth of penetration of the shockwave source when treating deep tissue structures.

Approved standard indications

Chronic tendinopathies:

- Plantar fasciitis with or without heel spur
- Achilles tendon
- Radial epicondylopathy (tennis elbow)
- Rotator cuff with or without calcification
- Patella tendon
- Greater trochanteric pain syndrome

Impaired bone healing function:

- Delayed bone healing
- Stress fractures
- Early stage of avascular bone necrosis (native X-ray without pathology)
- Early stage osteochondritis dissecans (OD) post-skeletal maturity

Urology:

- Lithotripsy (extracorporeal and endocorporeal)

Common empirically-tested clinical uses

Tendinopathy:

- Ulnar epicondylopathy
- Adductor syndrome
- Pes anserinus syndrome
- Peroneal tendon syndrome

Muscular pathologies:

- Myofascial syndrome (fibromyalgia excluded)
- Injury without discontinuity

Impaired wound healing

Burn injuries

Salivary stones

Exceptional indications/expert indications

Spasticity

Early stage osteochondritis dissecans (OD) pre-skeletal maturity

Apophysitis (Osgood Schlatter disease)

Peyronie's disease (IPP)

Uses under experimental conditions

Myocardial ischemia (extracorporeal/endocorporeal)

Peripheral nerve lesions

Abacterial prostatitis

Periodontal disease

Osteoarthritis

The authors group of the DIGEST	The ISMST Managing Board
Vinzenz Auersperg	Roland Hamisultane
Matthias Buch	Robert Gordon
Ludger Gerdesmeyer	Sergio Russo
Markus Gleitz	Heinz Kuderna
Rolf Rädcl	Vinzenz Auersperg
Jan-Dirk Rompe	Wolfgang Schaden
Wolfgang Schaden	Richard Thiele
Richard Thiele	Richard Coombs
Andreas Waubke	
Georg Wille	

Extracorporeal Shockwave in Hip Necrosis



Ching-Jen Wang, M.D.

Department of Orthopedic Surgery
Chang Gung University College of Medicine
Chang Gung Memorial Hospital Kaohsiung Medical Center
Kaohsiung, Taiwan
E-mail: w281211@adm.cgmh.org.tw

Treatment of osteonecrosis of the femoral head is stage dependent (1-4). For symptomatic hips, the principle is to preserve the femoral head in early cases (5). Conservative treatments are usually not successful, and core decompression with or without bone grafting is considered the gold standard (6-8). However, the results of core decompression are irregular and inconsistent, and many studies reported less satisfactory outcomes. Many patients eventually undergo total hip replacement (THR). The complications of THR in young active patients are high including thigh pain, polyethylene wear, mechanical loosening and infection (9).

Recently, extracorporeal shockwave (ESWT) (10-13), hyperbaric oxygen therapy (HBO) (14,15) and oral alendronate (16-19) were reported to be effective in early ONFH. We have investigated the results of single modality and multiple modalities in the treatment of early ONFH.

(1). We compared 23 patients with 29 hips treated with ESWT with 25 patients with 28 hips treated with core decompression and non-vascularized bone graft. The evaluations included pain score, Harris hip score, radiograph and MR imaging. At 25 to 35 months of follow-up, the results showed 79% improved, 10% unchanged and 10% worse for ESWT group; and 19% improved, 36% unchanged and 36% worse after surgery. THR was performed in 10% of ESWT group and 29% of surgical group. We concluded that ESWT appeared to be more effective than core decompression and bone grafting in early ONFH (12).

(2). We compared 25 patients with 30 hips treated with ESWT with 23 patients with 30 hips treated with combined ESWT and oral

alendronate. At 28 to 36 months of follow-up, the results were improved in 83%, unchanged in 7% and worse in 10% for ESWT group; and 77% improved, 13% unchanged and 10% worse for ESWT plus alendronate group. THR was performed in 10% of ESWT group and 10% of ESWT plus alendronate group ($P = 1.000$). We concluded that combined ESWT and alendronate produced comparable results as ESWT without alendronate. The joint effects of alendronate and ESWT are not realized in short-term (13).

(3). We compared 28 patients with 50 hips treated with cocktail therapy that consists of ESWT, HBO and alendronate) with 35 patients with 48 hips treated with ESWT. At a minimum of two years of follow-up, the results were improved in 74%, un-improved in 16% and worsened in 10% for cocktail group; and 79.2% improved, 10.4% un-improved and 10.4% worsened for ESWT group ($P = 0.717$). THR was performed in 10% of cocktail group and 10.4% of ESWT group ($P = 0.946$). No discernable differences between the two groups were noted on X-rays and MR images. We concluded that ESWT is effective with or without the concomitant use of HBO and alendronate. The synergistic effects of HBO and alendronate over ESWT are not apparent in short-term.

Despite the good clinical results, the exact mechanism of ESWT remains unknown. Likewise, the working mechanism of ESWT in ONFH is poorly understood. To elucidate the working mechanism of ESWT in early ONFH, we have compared the ESWT-treated femoral heads with non-ESWT-treated ones prior to surgery using histomorphological examination and immunohistochemical analysis. The ESWT-treated femoral heads showed significantly more viable bone and

less necrotic bone, higher cell concentration and more cell activities including phagocytosis than non-ESWT-treated specimens. In immunohistochemical analysis, the ESWT-treated femoral heads showed significant increases in vWF (von Willebrand factor) ($P < 0.01$), VEGF (vessel endothelial growth factor) ($P = 0.0021$), CD31 (PECAM-1 or platelet endothelial cell adhesion molecule-1) ($P = 0.0023$), Wnt3 (Wntless 3a) ($P = 0.008$) and PCNA (proliferating cell nuclear antigen) ($P = 0.0011$), and decreases in VCAM (vascular cell adhesion molecule) ($P = 0.0013$) and DKK1 (Dickkopf-1) ($P = 0.0007$) than non-ESWT-treated hips (Fig. 1). It appears that ESWT significantly promotes angiogenesis and osteogenesis with bone remodeling in ONFH of the hip (Rheumatology in press).

In conclusion, ESWT showed superior results than core decompression and non-surgical treatments such as HBO and alendronate in early ONFH. It appears that ESWT triggers the biological changes of angiogenesis and osteogenesis at the molecular level and results in tissue regeneration in hips with early ONFH.

References

1. Mont MA, Jones LC, Hungerford DS. Nontraumatic Osteonecrosis of the Femoral Head: Ten Years Later. *J Bone Joint Surg* 2006; 88A:1117-1132.
2. Ficat RF. Idiopathic bone necrosis of the femoral head: Early diagnosis and treatment. *J Bone Joint Surg* 1985; 67B: 3-9.
3. Gardeniers JWM. ARCO (Association Research Circulation Osseous) international classification of osteonecrosis. ARCO Committee on Terminology and Staging. Report on the committee meeting at Santiago de Compostella. ARCO Newsletter 1993; 5: 79-82.
4. Steinberg ME, Hayken GD and Steinberg DR. A quantitative system for staging avascular necrosis. *J Bone Joint Surg* 1995; 77B: 34-41.
5. Hungerford DS. Role of core decompression as treatment method for ischemic femur head necrosis. *Orthopæde* 1990; 19: 219-223.
6. Iorio R, Healy WL, Abramowitz AJ, Pfeifer BA. Clinical outcome and survivorship analysis of core decompression for early osteonecrosis of the femoral head. *J Arthroplasty* 1998; 13: 34-41.

7. Mont MA, Carbone JJ, Fairbank AC. Core decompression versus non-operative management for osteonecrosis of the hip. *Clin Orthop* 1996; 324: 169-178.
8. Scully SP, Aaron RK, Urbaniak JR. Survival analysis of hips treated with core decompression or vascularized fibular grafting because of avascular necrosis. *J Bone Joint Surg* 1998; 80A: 1270-1275.
9. Wei SY, Kliemkiewicz JJ, Lai M, Garino JP, Steinberg ME. Revision total hip arthroplasty in patients with avascular necrosis. *Orthopedics* 1999; 22(8): 747-57.
10. Ludwig J, Lauber S, Lauber HJ, et al. High-energy shockwave treatment of femoral head necrosis in adults. *Clin Orthop* 2001; 387: 119-126.
11. Lin PC, Wang CJ, Yang KD, Huang CC, Ko JY, Wang FS. Extracorporeal Shockwave Treatment for Osteonecrosis of the Femoral Head in systemic Lupus Erythematosus. *J Arthroplasty* 2006; 21(6):911-915.
12. Wang CJ, Wang FS, Huang CC, Yang KD, Weng LH, Huang HY. Treatment of osteonecrosis of the femoral head - Comparison of extracorporeal shockwave and core decompression and bone grafting. *J Bone Joint Surg* 2005; 87A: 2380-2387.
13. Wang CJ, Wang FS, Yang KD, Huang CC, Lee M SS, Chan YS, Wang JW, Ko JY. Treatment of osteonecrosis of the hip: comparison of extracorporeal shockwave with shockwave and alendronate. *Arch Orthop Trauma Surg* (in press).
14. Levin D, Norman D, Zinman C, et al. Treatment of experimental avascular necrosis of the femoral head with hyperbaric oxygen in rats: histological evaluation of the femoral heads during the early phase of the reparative process. *Experimental & Molecular Pathology* 1999; 67: 99-108.
15. Reis ND, Schwartz O, Militianu D, Romon Y, Levin D, Norman D, Melamed Y, Shupak A, Goldsher D, Zinman C. Hyperbaric oxygen therapy as a treatment for stage-I avascular necrosis of the femoral head. *J Bone Joint Surg (Br)* 2003; 85: 371-5.
16. Agarwala S, Jain D, Joshi VR, Sule A. Efficacy alendronate, a bisphosphate, in the treatment of AVN of the hip. A prospective open-label study. *Rheumatology (Oxford)* 2005; 44:352-9.
17. Agarwala S, Sule A, Pai BU, Joshi VR. Alendronate in the treatment of avascular necrosis of the hip. *Rheumatology (Oxford)* 2002; 41:346-7.
18. Desai MM, Sonone S, Bhasme V. Efficacy of alendronate in the treatment of avascular necrosis of the hip. *Rheumatology (Oxford)* 2005; 44:1331-2.
19. Lai KA, Shen WJ, Yang CY, Shao CJ, Hsu JT, Lin RM. The use of alendronate to prevent early collapse of the femoral head in patients with nontraumatic osteonecrosis. A randomized clinical study. *J Bone Joint Surg* 2005; 87A: 2155-2159.

Legends:

Figure 1. Microscopic findings with H-E stain showed significantly more viable bone and cell concentration and cell activity in study group than the control group.

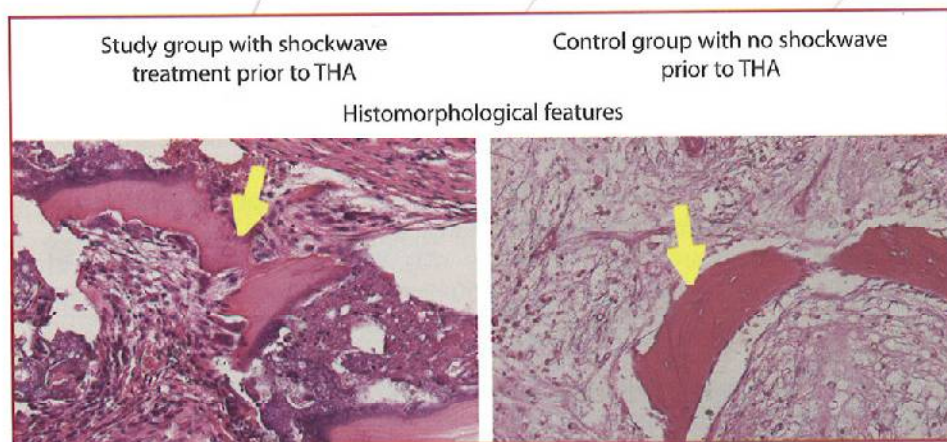


Figure 2. Microscopic findings with von Willenbrand factor stain showed significantly more new vessels (angiogenesis) in the study group than the control group.

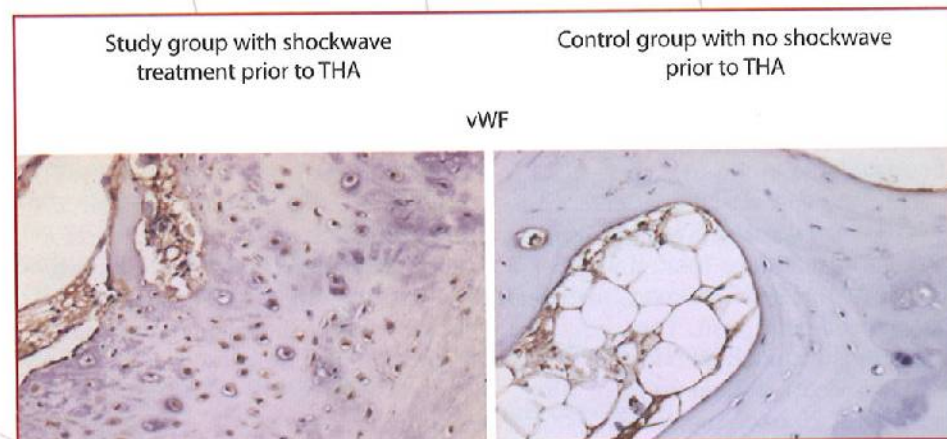


Figure 3. Microscopic features with immunohistochemical stain showed significantly higher VEGF expressions in the study group than the control group.

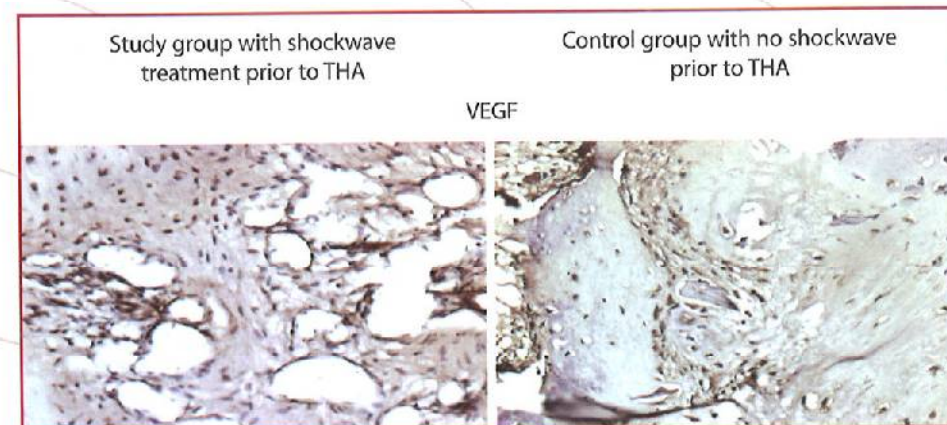


Figure 4. Microscopic features with immunohistochemical stain showed significantly more CD 31 expressions in the study group than the control group.

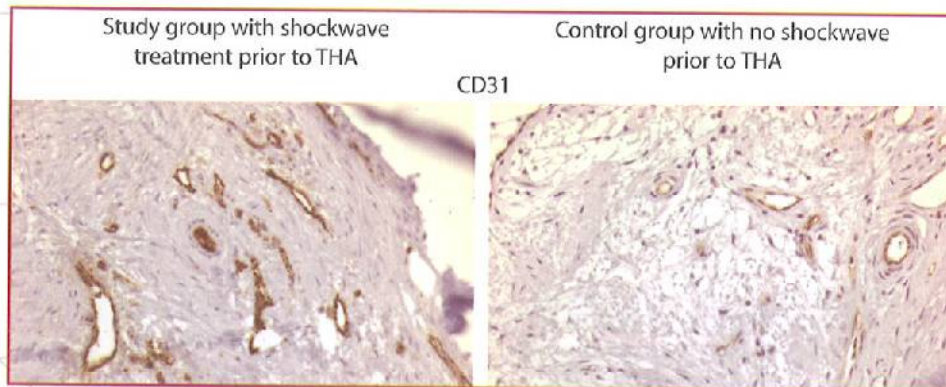


Figure 5. Microscopic features with immunohistochemical stain showed significantly less VCAM expressions in the study group than the control group.

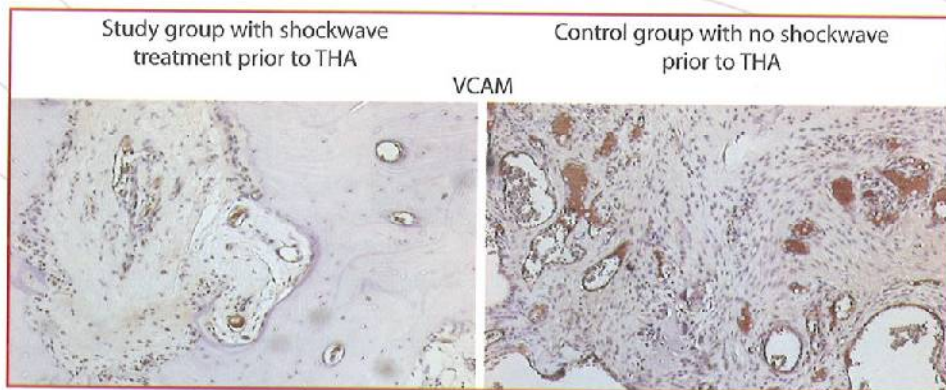


Figure 6. Microscopic features with immunohistochemical stain showed significantly more PCNA expressions and cell proliferations in the study group than the control group.

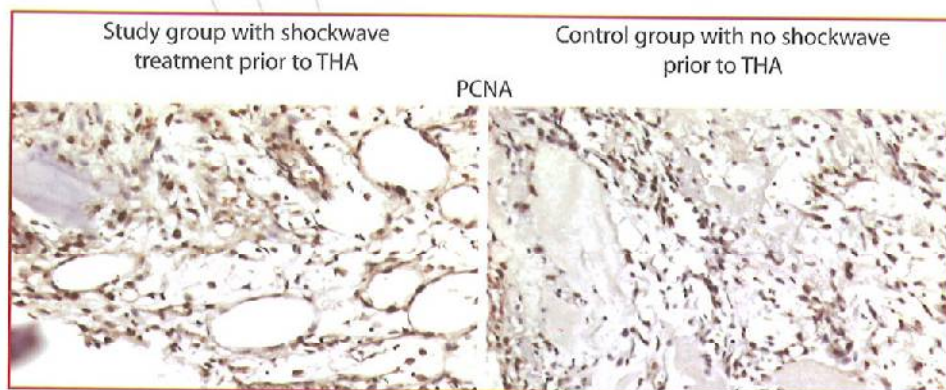


Figure 7. Microscopic features with immunohistochemical stain showed significantly less DKK1 expressions in the study group than the control group.

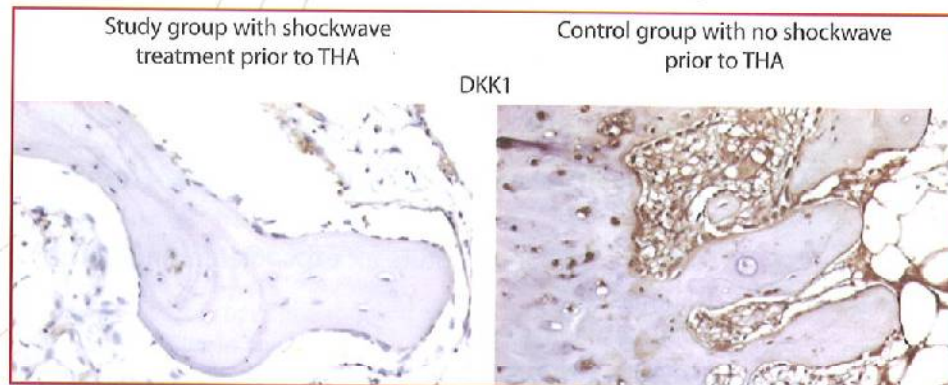
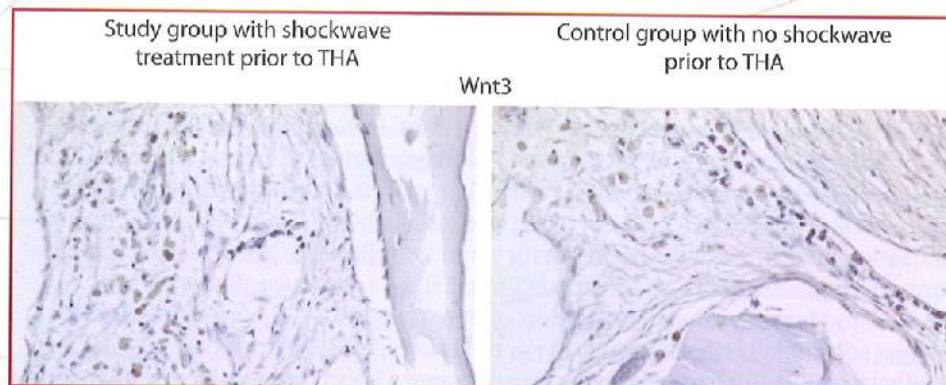
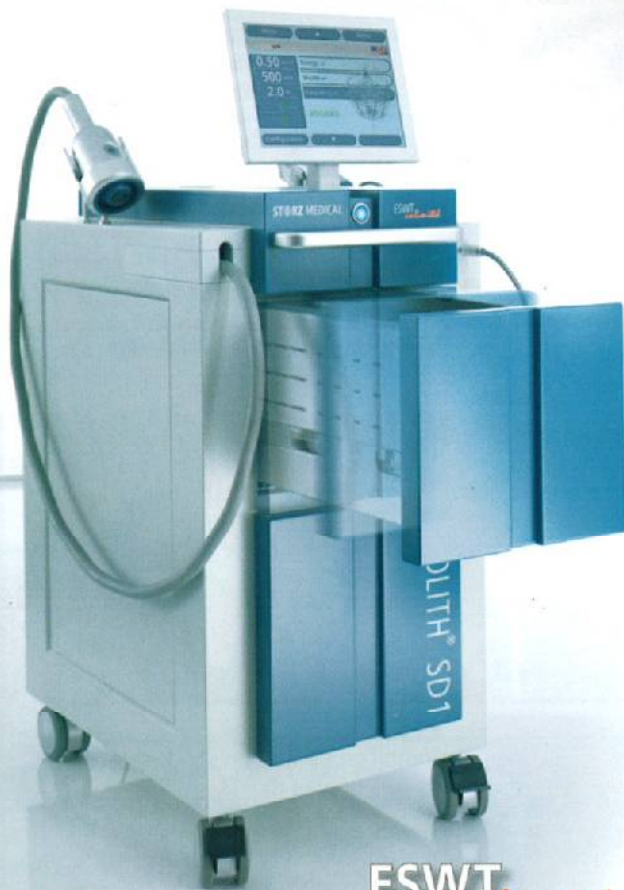


Figure 8. Microscopic features with immunohistochemical stain showed significantly more Wnt3 expressions in the study group than the control.



»Competence in Shock Wave«

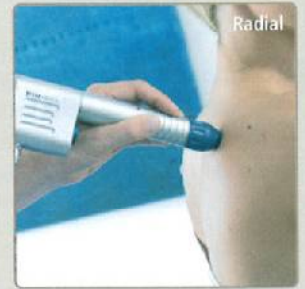

ESWT *unlimited*

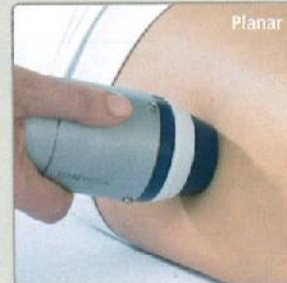STORZ MEDICAL



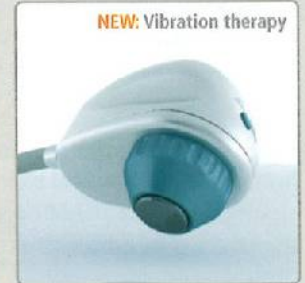Focused



Radial



Planar



NEW: Vibration therapy

DUOLITH® SD1

The versatile »high end« shock wave system

MORE INFORMATION:

STORZ MEDICAL AG · LOHSTAMPFESTRASSE 8 · CH-8274 TÄGERWILEN
TEL: +41 (0)71 677 45 45 · FAX: +41 (0)71 677 45 05
MAIL@STORZMEDICAL.COM · WWW.STORZMEDICAL.COM

When is the right time for ESWT? Influence of ESWT on Ischemia Induced Tissue Necrosis and Its Correlation with Application Time



**Rainer Mittermayr,^{1,2} Joachim Hartinger,¹
Martina Hofmann,¹ Wolfgang Schaden,² Heinz Redl¹**

¹ Ludwig Boltzmann Institute for experimental and clinical
Traumatology

AUVA Research Center
Austrian Cluster for Tissue Regeneration

² AUVA Trauma Center Meidling
Vienna, Austria

Delayed/Non-healing or chronic wounds are an enormous challenge (physically, but also mentally) to each patient affected. Such wounds significantly impair the quality of life for millions of people. Intensive treatment is required and imparts an enormous burden on society in terms of lost productivity and health care costs.

Tissue ischemia/hypoxia is one of the major factors affecting an uncomplicated wound healing process potentially resulting in a chronic wound condition. Numerous surgical specialties are confronted with compromised tissue perfusion, often resulting in extensive operative revisions. This is especially seen in

patients with co-morbidities such as diabetes and peripheral ischemic diseases (e.g. arteriosclerosis). The intrinsic capacity for physiological tissue regeneration is often severely impaired in these patients. If wounds require skin flap coverage in this patient population, then the transferred flaps may also be negatively affected by the underlying pathology. Skin flap surgery using autologous donor tissue is the treatment of choice for patients with large wounds or tissue defects. Depending on the size of the defect, either skin grafts, muscular flaps or composite

flaps may be used. Necrosis of skin flaps, either partial or complete, remains a serious complication in skin flap surgery. Insufficient arterial (in)flow with the accompanying decreased nutritional supply to hypoxic/ischemic tissues can be potentially overcome by therapeutic

angiogenesis.¹ Numerous angiogenic factors have been studied for efficacy, for which an invasive approach with concomitant application of exogenous substances is common.²⁻⁴ The mode of administration for angiogenic factors has also been studied, as the intended clinical use and efficacy are a concern when known adverse effects occur with systemic administration.⁵⁻⁷

Application of shockwaves in different medical indications has continuously expanded since its introduction in urology for concrement disintegration. Since then, technique as well as application mode have been steadily modified and improved. Recently, extracorporeal shockwave therapy (ESWT) is being successfully used for treating chronic or delayed/disturbed healing wounds. Distinct advantages over other clinical but also experimental therapeutic approaches are the non-invasiveness and the avoidance of "exogenous medication" via various substances (e.g. growth factors, vasodilators). Although the mechanisms of ESWT in ischemic soft tissue pathologies are still uncertain, it seems that shockwaves affect a complex spectrum of cellular and bio-molecular functions.

ESWT in experimental flap surgery

Effectiveness of ESWT in reducing ischemia-induced tissue necrosis was already shown experimentally in a rodent epigastric flap model (Figure 1).⁸ After rendering a certain part of the flap ischemic (ligation and dissecting a vascular bundle), shockwaves were immediately applied to the ischemic challenged tissue. Seven days after, the area of necrosis was substantially reduced in comparison to the untreated control group. Although this finding is of enormous clinical interest, clinicians (especially reconstructive trauma surgeons) are regularly confronted with delayed (e.g. 24 hours) tissue necrosis following reconstructive (flap) surgery. Thus, a treatment option to intervene in such cases with already macroscopically visible failure is highly desirable. ESWT fulfills this requirement as seen in delayed treatment of the above mentioned rodent epigastric flap performed in our institution. The study follow up showed that the ischemic challenged

flap developed significantly less necrosis as compared with the control group (Figure 2). A physiological process during wound healing is the wound contraction and reflects in some manner the quality of wound healing (collagen composition). Wound contraction should be minimal, especially for wound areas adjacent to joints which have to be covered by skin transplants or flap transfer. Preventing or minimizing contraction (extensive scar formation) results in less constrained range of motion in the involved joints and avoids surgical revisions. But also areas adjacent to orifices (face, beside the aesthetic point of view) are vulnerable to contraction and should be kept at a minimum. In the same study set up, less flap contraction concomitant with less necrotic area was observed. Encouraged by these findings, we addressed a further issue in elective treatment. Although in elective surgery a broad spectrum of possible complications can effectively be avoided, a residual risk which is incalculable exists especially in patients with co-morbidities (e.g. disturbed wound healing in diabetic patients). A tremendous amount of professional care efforts (wound care, wound revision) and social financial burden could be reduced if an elective treatment existed which would prepare the tissue as needed for the anticipated surgical intervention. Surgical procedures in a two stage manner were evaluated to reduce necrosis and showed effectiveness.⁹ For instance, in the first stage of flap surgery, only incisions will be made to induce the following increased tissue perfusion and to prepare the tissue for transfer in the second stage. Although this procedure shows a positive impact in the latter flap outcome, it nevertheless represents an invasive approach with its side effects (e.g. infection risk). When we experimentally applied shockwaves to the flap prior to surgery, we were able to see a reduction in necrotic area equal to the above mentioned delayed treatment. This is of great clinical relevance, because clinicians would have the opportunity to selectively treat patients prior to intended surgery who are at high-risk of suffering from wound healing disturbances afterwards.

These findings in reducing tissue necrosis by ESWT are comparable with those studies which used exogenous growth factors (e.g. therapeutic angiogenesis) in the same indication.^{10,11} An enormous advantage, however, over these studies is the non-invasiveness of our approach in the application of shockwaves. Additionally, no adverse effects over the entire study period were observed. Further advantages are that the application is simple, it is well-received by the patients, and is cost effective.

Compromised tissue perfusion and the influence of ESWT

Probably one of the worst scenarios in reconstructive surgery (e.g. after free flap transfer with micro-anastomosis) represent tissue loss due to hypoxia or ischemia, as already mentioned above. Several apparatuses and methods exist for early detection of this unfavorable condition. However, treatment options after verification of this status are scarce. In the described animal model, flap ischemia could be verified beyond doubt by clear blue demarcation 24 hours after vessel ligation. In addition, a clinically used, non-contact, Doppler based system could confirm the clinical macroscopic finding. The principle is that a low intensity laser light beam scans the surface of the skin and generates a 2-dimensional image of flap perfusion. With this technology the ischemic impact was confirmed in all test animals by a distinct reduction in flap perfusion.

Recent studies, predominantly experimental ones, demonstrated that ESW treated tissues, which were vulnerable to disturbed wound healing, showed modified release kinetics of essential growth factors LIT and induced angiogenesis. This improved circulation may have distinct benefits in wounds subjected to healing disturbances. Growth factors which are of interest included among others angiogenesis related factors and their early expression patterns. It was shown that these growth factors were up-regulated. This results in angiogenesis with concomitant improved tissue perfusion, increased cell proliferation and accelerated tissue regeneration

and healing.^{12,13} Using the Doppler based perfusion imaging system, a clear enhancement of circulation in the experimental flaps was noticeable at the time point when shockwaves were applied (**Figure 3**). This supports the hypothesis that angiogenesis with concomitant improved tissue perfusion/improved blood supply is one of the mechanisms of ESWT in ischemic/hypoxic wounds.

Transplant surgery is often confronted with limited healing of transferred tissue to the wound bed. Possible causes are seroma formation which prevents the nutritional supply from the wound bed to the overlying tissue, ultimately resulting in flap loss. Additionally, the lack of full tissue contact prevents the formation of new vessels (angiogenesis) which are mandatory for flap outcome, especially when subjected to a certain degree of hypoxia (ischemia). Macroscopic evaluation in our experiments showed that transplanted flaps treated with shockwaves have better adherence to the wound bed in the ischemic challenged flap area in comparison to controls which were left untreated. Surprisingly, this was not due to reduced seroma formation (nearly equal amounts between shockwave groups and control group).

In summary ESWT was found as a feasible therapeutic tool in preventing necrosis in ischemic challenged tissue. This therapeutic effect was seen as time-independent. This is of great clinical relevance, because the clinicians have a certain therapeutic window in which ESWT shows its effectiveness. Tissue subject to hypoxia/ischemia after surgery is eligible for this non-invasive, cost-effective approach and may help reduce extensive surgical revisions and prolonged wound care. Likewise, patients susceptible to wound healing disturbances could be treated prior to necessary surgical interventions, thus minimizing postoperative complications.

References

1. Hockel, M., Schlenger, K., Doctrow, S., Kissel, T. & Vaupel, P. Therapeutic angiogenesis. *Arch. Surg.* 128, 423-429 (1993).
2. Pepper, M. S. Manipulating angiogenesis. From basic science to the bedside. *Arterioscler. Thromb. Vasc. Biol.* 17, 605-619 (1997).
3. Zhang, F., Waller, W. & Lineaweaver, W. C. Growth factors and flap survival. *Microsurgery* 24, 162-167 (2004).
4. Vranckx, J. J. et al. In vivo gene delivery of Ad-VEGF121 to full-thickness wounds in aged pigs results in high levels of VEGF expression but not in accelerated healing. *Wound. Repair Regen.* 13, 51-60 (2005).
5. Kryger, Z. et al. The effects of VEGF on survival of a random flap in the rat: examination of various routes of administration. *Br. J. Plast. Surg.* 53, 234-239 (2000).
6. Eppler, S. M. et al. A target-mediated model to describe the pharmacokinetics and hemodynamic effects of recombinant human vascular endothelial growth factor in humans. *Clin. Pharmacol. Ther.* 72, 20-32 (2002).
7. Yang, R. et al. Substantially attenuated hemodynamic responses to Escherichia coli-derived vascular endothelial growth factor given by intravenous infusion compared with bolus injection. *J. Pharmacol. Exp. Ther.* 284, 103-110 (1998).
8. Meirer, R., Kamelger, F. S., Huemer, G. M., Wanner, S. & Piza-Katzer, H. Extracorporeal shock wave may enhance skin flap survival in an animal model. *Br. J. Plast. Surg.* 58, 53-57 (2005).
9. Wong, M. S. et al. Basic fibroblast growth factor expression following surgical delay of rat transverse rectus abdominis myocutaneous flaps. *Plast. Reconstr. Surg.* 113, 2030-2036 (2004).
10. Michlits, W., Mittermayr, R., Schafer, R., Redl, H. & Aharinejad, S. Fibrin-embedded administration of VEGF plasmid enhances skin flap survival. *Wound. Repair Regen.* 15, 360-367 (2007).
11. Mittermayr, R. et al. Abstract at TERMIS 2005, Stuttgart. *Wound.Repair Regen.* 2008. Ref Type: In Press
12. Wang, C. J. An overview of shock wave therapy in musculoskeletal disorders. *Chang Gung. Med. J.* 26, 220-232 (2003).
13. Nishida, T. et al. Extracorporeal cardiac shock wave therapy markedly ameliorates ischemia-induced myocardial dysfunction in pigs in vivo. *Circulation* 110, 3055-3061 (2004).

Figures:

Figure 1. Application of shockwaves in the ischemic third of the flap using ultrasound conduction gel. It is an epigastric flap with dimensions of approximately 8x8 cm, divided into vital, transition and ischemic areas (blue lines).

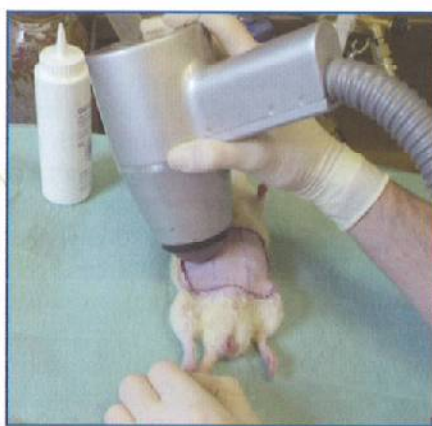

Figure 2. Necrosis of entire flap on day 7 after surgery. Representative images of each group are depicted. A clear reduction of tissue necrosis is noticeable in all shockwave treatment groups in comparison to the control group. Within the different treatment groups no differences were found. (A) Control group (B) 24h pre-OP group (C) post-OP group (D) 24h post-OP group.

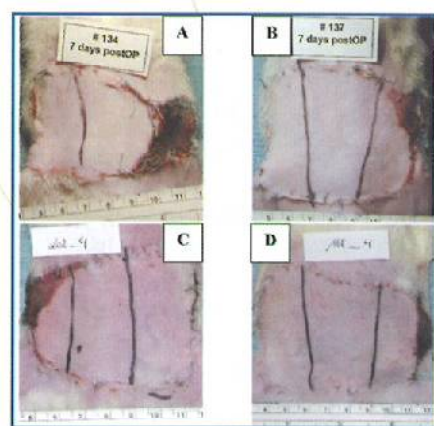
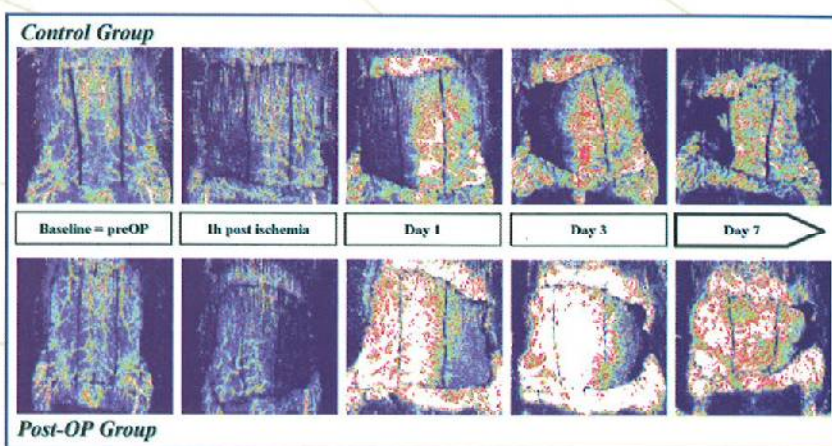
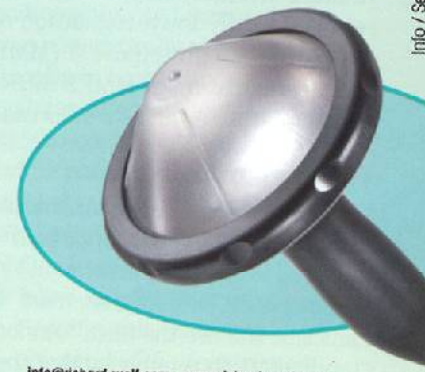
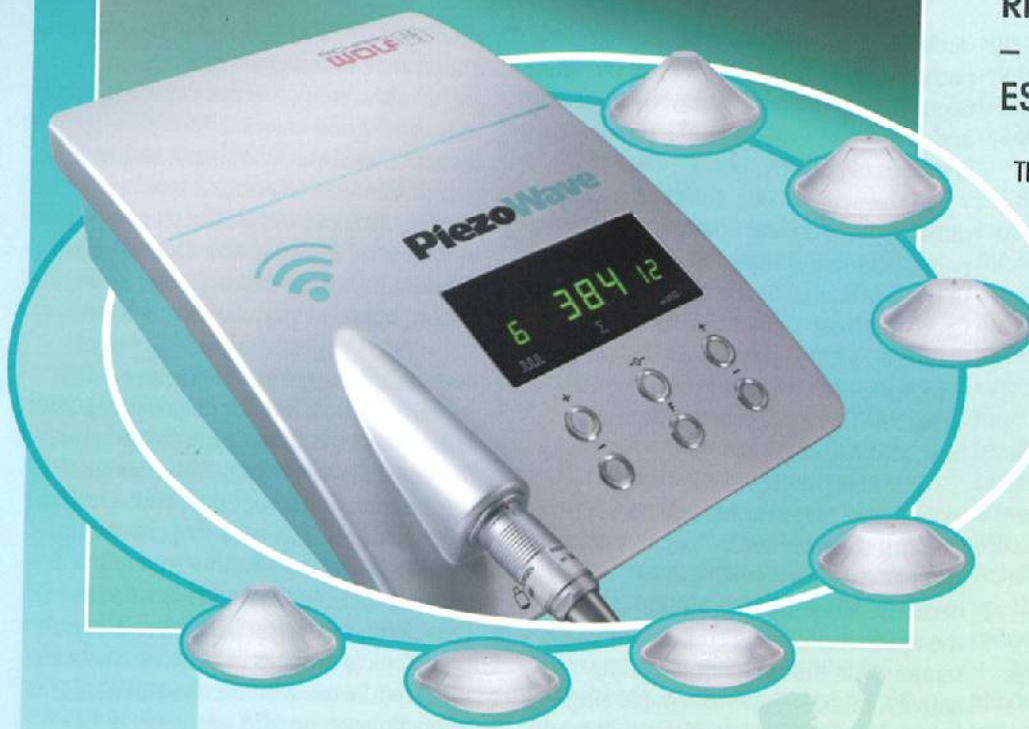
Figure 3. Superficial flap perfusion assessed by LDI system. Depicted are typical perfusion images in the control group and post-OP group during the 7 day interval. An increase in perfusion on day 7 postoperatively is evident in the flaps which were treated with shockwaves. Each group had a drop in perfusion post surgery caused by ligation of the neurovascular bundle (1h post ischemia).



Richard Wolf **PiezoWave** – new therapy concept for ESWT / TPST indications!

The new Richard Wolf **PiezoWave** gives you the option of universal application for numerous pain therapy indications. The ESWT / TPST system and its successful application not only means a high degree of patient satisfaction but also economic impulses and greater profitability in your practice.



RICHARD WOLF
spirit of excellence

RICHARD WOLF GmbH · 75434 Knittlingen · Germany · PF 1164 · Phone +49 70 43 35-0 · Fax +49 70 43 35-300 · Austria · Belgium / Netherlands · France · Germany · India · USA · UK · U.A.E.

info@richard-wolf.com · www.richard-wolf.com

Info / Service-Nr. 104.07 / www.stuetzlepartner.de

Mid-portion Achilles tendinopathy - What role is there for shock wave treatment?



Jan D. Rompe MD

Professor of Orthopaedics, OrthoTrauma Evaluation Center, Oppenheimer Str. 70, D-55130 Mainz, Germany
e-mail: proffrompe@web.de

Introduction

The incidence of midsubstance Achilles tendinopathy has risen. The condition is common in recreational and competitive athletes, particularly amongst runners and athletes participating in racquet sports, track and field, volleyball and soccer. The incidence of Achilles tendinopathy in top level runners has been estimated at between 7 and 9%. Of note, a 10-fold increase in Achilles tendon injuries has been reported in runners compared to age matched controls. However, Achilles tendinopathy is also common in the sedentary population. In a recent study, 31% of 58 Achilles tendinopathy patients did not participate in vigorous physical activity.

Aetiology and pathophysiology

Tendon injuries can be acute or chronic, and are caused by either intrinsic or extrinsic factors. In acute trauma, extrinsic loads exceed the tensile strength of the tendon. Overuse injuries generally have a multifactorial origin. Gastrocnemius-soleus dysfunction, advanced age, body weight, pes cavus, and lateral ankle instability are common intrinsic risk factors. Changes in training pattern, poor technique, previous lower extremity injuries, footwear and environmental factors such as training on hard, slippery or slanting surfaces are extrinsic factors which may also predispose the athlete to Achilles tendinopathy.

The relationship between excessive tendon loading, clinical symptoms, and abnormal histopathology remains unclear. Excessive loading of tendons during vigorous physical training is generally regarded as the main pathological stimulus for degeneration but not all data supports this hypothesis. In one study on chronic Achilles tendinopathy (342 tendons), physical activity was not correlated to the extent of histopathological changes, suggesting that physical activity may be more important in evoking the symptoms than being the root cause of pathology. The lack of association between activity, pain and structural abnormality has also been reported in other tendons. Further pathological changes are seen not uncommonly seen on imaging studies in asymptomatic individuals who are physically active.

Tendons respond to repetitive overload beyond physiological threshold by either inflammation of their sheath, degeneration of their body, or a combination of both. It remains unclear whether different stresses induce different responses. Tendon damage may also occur from

stresses within physiological limits, as frequent cumulative microtrauma may not allow enough time for repair.

Free radical damage occurring on reperfusion after ischaemia, hypoxia, hyperthermia and impaired tenocyte apoptosis have been linked with tendinopathy, as have been local administration of cytokines and inflammatory agents. Ciprofloxacin causes enhanced interleukin-1-mediated MMP3 release, inhibited tenocyte proliferation, and reduced collagen and matrix synthesis. Changes in the expression of genes, regulating cell-cell and cell-matrix interactions in Achilles tendinopathy, have been reported, with down-regulation of matrix metalloproteinase 3 (MMP 3) and up-regulation of MMP2 mRNA in tendinopathic Achilles tendon samples.

Histopathology

The pathologic label 'tendinosis' is used to describe the disorganized impaired healing response in tendinopathy. Despite that, most clinicians still use the term "tendonitis" or "tendonitis", thus implying that the fundamental problem is inflammatory. I advocate the use of the term **tendinopathy** as a generic descriptor of the clinical conditions in and around tendons arising from overuse, and suggest that the terms tendinosis, tendonitis and tendinitis only be used after histopathological examination.

Various types of degeneration may be seen in tendons, but in the Achilles tendon 'mucoid' or 'lipoid' degeneration is usually seen. In mucoid degeneration, light microscopy reveals large mucoid patches and vacuoles between fibres. In lipoid degeneration, abnormal intratendinous accumulation of lipid occurs, with disruption of collagen fibre structure.⁴⁰ In general, tendinopathy is characterized by cellular activation and increase in cell numbers, increase in ground substance, collagen disarray and neovascularisation, with an appearance of a failed healing response. Histological evaluation of Achilles tendon biopsies, intratendinous microdialysis and contemporary molecular biology techniques (cDNA-arrays, real-time quantitative PCR) of appropriately prepared biopsy tissue, all failed to show evidence of prostaglandin-mediated inflammation.

Clinical Presentation

Pain is the cardinal symptom of Achilles tendinopathy. Pain occurs at the beginning and a short while after the end of a training session, with a period of

diminished discomfort in between. As the pathological process progresses, pain may occur during the entire exercise session, and, in severe cases, it may interfere with activities of daily living.

In the acute phase, the tendon is diffusely swollen and edematous, and on palpation tenderness is usually greatest 2 to 6 cm proximal to the tendon insertion. Crepitation is common. In chronic cases, exercise-induced pain is still the cardinal symptom, but crepitation and edema diminish. The tendon becomes thick, firm, and nodular.

The first priority of the clinical examination is to exclude acute rupture. The calf squeeze test is easy to perform and has excellent validity. After demonstrating that the tendon is intact, the examination should aim to provoke tendon pain during tendon-loading activity. In most patients, simple single-leg heel raises will be sufficient to cause pain. In more active individuals, however, it may be necessary to ask the patient to hop on the spot, or hop forward, to further load the tendon and reproduce pain. The differential diagnoses include tenosynovitis or dislocation of the peroneal or other plantar flexor tendons, irritation or neuroma of the sural nerve, and systemic inflammatory disease. Although these conditions may cause pain in and also around the Achilles tendon, true Achilles tendon pain is nearly always confined to the tendon itself.

Imaging methods

Achilles tendinopathy is a clinical diagnosis mainly based on a careful history and detailed clinical examination. At times, however, diagnostic imaging may be required to verify a clinical suspicion or, occasionally, to exclude other musculoskeletal disorders.

Ultrasonography is widely used in European countries. It is easily available, quick, safe, and inexpensive. However, ultrasound is operator-dependent, has somewhat limited soft tissue contrast, and is not as sensitive as MRI.

Colour and power Doppler have recently added a new dimension to standard ultrasound tendon imaging. This imaging demonstrates blood flow in tissues. Alfredson's group reports that, in normal Achilles tendons, blood flow was not detectable, but colour Doppler often reveals blood flow in pathological tendons. Such blood flow was linked to greater pain scores, poorer function and longer standing symptoms in the Achilles tendon, compared with control participants who have no visible flow. The association, however, was not

absolute. The long term clinical importance of blood vessels in pathological tendon is not clear, especially as more refined examinations demonstrated vascularization also in non-tendinopathic Achilles tendons. Koenig ultrasonically detected arteries in all normal tendons with Doppler after contrast injection. Accordingly, abnormalities in vascularity might be age-related, and age-stratified normal materials is needed to define normality.

MRI is also a helpful diagnostic study. MRI provides extensive information on the internal morphology of tendon and the surrounding structures, and is useful to evaluate various stages of chronic degeneration and for differentiation between peritendinitis and tendinosis. Excellent correlation between MRI and pathological findings at surgery has been reported. Areas with increased signal intensity seen on MRI correspond with areas of altered collagen fiber structure and increased interfibrillar ground substance (proteoglycans and hydrophilic glycosaminoglycans). Signal intensity on MR has been associated with clinical outcome.

Treatment

Both conservative and nonoperative treatment have a role in the management of Achilles tendinopathy. The initial treatment is nonoperative. Early intervention is paramount.

Seeking medical attention at an early stage may improve outcome, as treatment becomes more complicated and less predictable when the condition becomes chronic.

Unfortunately, the scientific level of evidence for most of conservative and surgical treatments remains low.

Initial conservative management most commonly consists of a combination of strategies, including abstention from the activities that caused the symptoms, and correction of training errors, foot malalignments, decreased flexibility, and muscle weakness.

Treatments that have been investigated with randomised controlled trials include nonsteroidal anti-inflammatory medication (NSAID), eccentric exercise, glyceryl trinitrate patches, electrotherapy (microcurrent and microwave), sclerosing injections, and shock wave treatment. There are no randomized or prospective studies that compare different conservative and surgical treatment regimens.

Nonsteroidal antiinflammatory drugs (NSAIDs) are frequently used in the

management of acute athletic injuries, often for analgesic purposes.

The evidence to support enhanced healing is limited. There is some data that suggests that NSAIDs impair tendon healing. In one study, NSAIDs were shown to inhibit tendon cell migration and proliferation. NSAIDs had little or no effect on the clinical outcome.

Cryotherapy has been regarded as a most useful intervention in the acute phase of Achilles tendinopathy, as it has an analgesic effect, reduces the metabolic rate of the tendon, and decreases the extravasation of blood and protein from new capillaries found in tendon injuries. Intermittent cryotherapy of 3x10 min significantly decreased local Achilles tendon mid-portion capillary blood flow by 71%. Postcapillary venous filling pressures were reduced during cryotherapy, favouring capillary venous outflow of the healthy Achilles tendon.

Peritendinous injections with corticosteroids are still controversial, evidence for their effectiveness is missing, and there are no good scientific reasons to support their use. The short term effect of corticosteroid injection has been shown in the Achilles with improvement in walking pain and reduction in tendon diameter as measured by US. Intratendinous injections of corticosteroids are to be avoided due to their catabolic effects.

Eccentric training is a popular treatment in Scandinavia. Several centres have reported good and excellent results with this treatment regime. Alfredson evaluated a 12-week eccentric calf muscle training programme for painful midportion Achilles tendinopathy. Alfredson's model of eccentric training involves no concentric loading and emphasizes the need for patients to complete the exercise protocol despite pain in the tendon. Good short- and long-term clinical results have been reported. This program was effective when other conventional management modalities (rest, NSAIDs, change of shoes, orthoses, physical therapy, ordinary training programs) had failed, and the training was successful in approximately 90% of patients.

Not all trials involving eccentric training have been favourable. Recently, a Danish group examined found no difference when comparing the effect of eccentric exercises with conventional

stretching exercises. In 2006 Sayana and Maffulli studied the effects of eccentric exercises in sedentary non-athletic patients. Forty-four percent of the thirty-four patients with a clinical diagnosis of unilateral tendinopathy of the main body of the Achilles tendon did not improve with the eccentric exercise regimen.

None of several possible explanations for the clinical effectiveness of eccentric exercise have been fully investigated. Volume and signal on MRI are increased. Type I collagen production is affected, and, in the absence of ongoing insult, this might increase the tendon volume over the longer term. An influence of the mechanical insult of the training program on the pain producing nerves and paratendinous blood flow has also been discussed. In one observational study, patients satisfied with the result of the eccentric training regimen had no remaining neovascularisation, and all patients with a poor clinical result continued to demonstrate neovascularisation. This hypothesis was not supported by recent publications.

Alfredson and Cook suggested injection of a vascular sclerosant (Polidocanol) - an aliphatic non-ionised nitrogenfree substance with a sclerosing and anaesthetic effect - in the area with neovascularisation anterior to the tendon. Six months after this injection, eight of ten tendons were pain-free after a mean of two treatments. Those tendons that were painfree had no neovascularisation outside or inside the tendon, but vessels remained in the two non-successfully treated patients. In a longer follow-up study color Doppler ultrasound showed no, or a few, remaining neovessels in the majority of the successfully treated tendons. As vessel number has been shown to correlate with tendon thickness, treatment that decreases vessel number is likely to also affect tendon thickness.

Topical glyceryl trinitrate has been investigated in randomised controlled trials in the Achilles, elbow and supraspinatus tendons as an adjunct to an eccentric exercise program. The topical glyceryl trinitrate was applied to the tendon as a patch that was renewed each day for six months. The treatment was compared to a placebo patch, and pain and function were measured over 6 months. In the Achilles tendon, activity pain in the treatment group was reduced at 12 and 24 weeks compared to placebo and it also improved outcomes at six months. This study

supported the use of an eccentric exercise program, as 49% of the non-GTN group also reported excellent outcomes.

Shock Wave Treatment (SWT) has emerged as another effective treatment for Achilles tendinopathy. Pilot studies investigating the effects of SWT on Achilles tendinopathy have been promising. Lohrer et al. reported significant pain reduction and increased functionality in patients with Achilles tendinopathy who were treated with radial SWT. There was no control group, however. Perlick et al. compared SWT with surgery as a treatment for chronic Achilles tendinopathy. At 1-year follow-up, there was a statistically significant reduction in pain in both groups.

In a small, randomized, double-blinded, placebo-controlled trial consisting of 39 patients, Peers reported his experience using low-energy SWT for the treatment of patients with chronic Achilles tendinopathy. At 12-week follow-up, the 20 treated patients had significantly improved VAS when compared with an untreated control group. A 77% success rate was reported.

Furia evaluated the effects of a single high-energy SWT on a consecutive series of 35 patients with chronic Achilles tendinopathy that had not responded to nonoperative management, 33 patients with chronic insertional Achilles tendinopathy were not treated with SWT, but instead were treated with additional forms of nonoperative therapy (control group). At one month, 3 months, and 12 months following treatment, the mean VAS improved significantly more in the SWT group. Patients in the SWT group treated under local anaesthesia had a significant lower improvement in VAS score than the corresponding gain in the non-local anesthesia subgroup.

In a recent randomized, controlled trial, Rompe compared the effectiveness of three management strategies for the treatment of noninsertional Achilles tendinopathy. Group one was treated with eccentric loading exercises, group two was treated with repetitive lowenergy radial SWT, and group 3 was treated with a 'wait-and-see' approach. All of the 75 enrolled patients had received unsuccessful management with traditional nonoperative methods for a minimum of 3 months. At 4 months from baseline, the VISA A Score increased in all groups, pain rating decreased in all groups. For all outcome measures, groups 1 and 2 did not differ

significantly. For all outcome measures, groups 1 and 2 showed significantly better results than group 3.

Costa, in an earlier publication, had deviated from the protocols used by Furia and Rompe. In the Costa trial, 49 patients were treated once a month for 3 months. The primary outcome measure was a reduction in Achilles tendon pain during walking at 4 weeks after the last SWT/sham SWT. No difference in pain relief was found between the shock wave therapy group and the control group.

None of several possible explanations for the clinical effectiveness of shock wave treatment have been fully investigated. The rationale for SWT in clinical use is inhibition of pain receptors and stimulation of soft-tissue healing. In the periphery, SWT leads to selective dysfunction of sensory unmyelinated nerve fibres without affecting the large myelinated nerve fibres responsible for motor function. For high energy treatment, this selective destruction of sensory unmyelinated nerve fibres within the focal zone of SWT may contribute to clinically evident long-term analgesia. For low-energy application, analgesia may result from shock wave-induced destruction of sensory nerve fibres with liberation of neuropeptides, such as calcitonin gene related peptide (CGRP), resulting in a local neurogenic inflammation in the focal area with subsequent prevention of sensory nerve endings from re-innervating this area. Centrally, the findings of a reduction in the number of neurons immunoreactive to CGRP and substance P without a reduction in the total number of neurons within the lower lumbar dorsal root ganglia (DRG) probably are a secondary effect following the decrease in the number of sensory nerve fibres in the focal zone of shock wave application. Similar results were reported for neurons immunoreactive for CGRP within the DRG of the mouse after transaction of the sciatic nerve. Therefore, both the peripheral and central nervous system may play a pivotal role in mediating shock wave-induced long-term analgesia.

In the only human experiment, Klonschinski investigated whether the biological effects of SWT differed between application with and without an LA. SWT was applied to the skin either after local pre-treatment with lidocaine cream LA or without LA to the corresponding location of the contralateral limb. Increasing energy flux density led to a significant increase of pain. LA significantly attenuated this pain and significantly inhibited C-fibre activity,

with a significant reduction in local vasodilation. Reduction in vasodilation correlated positively with the amount of energy flux density applied. SWT without LA resulted in a dose-dependent lower pressure pain threshold, i.e. sensitization, than did SWT with LA.

With regard to soft-tissue healing, Taiwanese research groups investigated the effect of low-energy SWT on neovascularization at the tendon-bone junction in rabbits. Low-energy SWT (LESWT) produced a significantly higher number of neo-vessels and angiogenesis-related markers, including endothelial nitric oxide synthase, vessel endothelial growth factor and proliferating cell nuclear antigen than the control without SWT. Only an optimal number of 200-500 impulses of LESWT promoted clinical resolution of Achilles tendinopathy by inducing TGF-beta1 and IGF-I and increased the contact between bone and tendon as well as tensile strength.

Surgical treatment

In 24% - 45.5% of patients with Achilles tendinopathy, conservative management is unsuccessful, and surgery is recommended after exhausting conservative methods of management, often tried for at least six months. For the Achilles tendon, frequency of surgery has been shown to increase with patient age, duration of symptoms, and occurrence of tendinopathic changes.

The objective of surgery is to excise fibrotic adhesions, remove degenerate nodules and make multiple longitudinal incisions in the tendon to detect intratendinous lesions and to restore vascularity and possibly stimulate the remaining viable cells to initiate cell matrix response and healing. Recent investigations show that multiple longitudinal tenotomies trigger neoangiogenesis at the Achilles tendon, with increased blood flow. This would be due to the fact that, in the failed healing response typical of tendinopathy, vascularisation, though present, is haphazard and non-functional. This would result in improved nutrition and a more favourable environment for healing. Patients are encouraged to weight bear as soon as possible after surgery. Most authors report excellent or good results in up to 85% of cases, although this is not always observed in routine non-specialised clinical practice. Percutaneous tenotomy resulted in 75% reporting good or excellent results after 18 months. Open surgery for Achilles tendinopathy has shown that the outcomes are better

for those tendons without a focal lesion compared with those with a focal area of tendinopathy. At seven months after surgery, 67% had returned to physical activity, 88% in the no lesion group and 50% in the group with a focal lesion.

It is difficult to compare the results of studies as most studies do not report their assessment procedure. Also, no prospective randomized studies comparing operative and conservative treatment of Achilles tendinopathy have been published. Thus, most of our knowledge on treatment efficacy is based on clinical experience and descriptive studies. Under all circumstances, Achilles tendon surgery requires extensive post-surgical rehabilitation, and the results after surgery may only be as good as the strength and functional capacity that is regained. Adequate attention to rehabilitation is likely to improve outcomes for those that are surgically treated.

Conclusions

Although Achilles tendinopathy has been extensively studied, there is a clear lack of properly conducted scientific research to clarify its etiology, pathology and optimal management. Most patients respond to conservative measures if the condition is recognised early, while continuing the offending activities leads to chronic changes which are more resistant to non-operative management.

Teaching patients to control the symptoms may be more beneficial than leading them to believe that Achilles tendinopathy is fully curable. In randomised controlled studies, painful eccentric heavy loading exercises and shock wave treatment have shown encouraging outcomes. Surgery usually involves removal of adhesions and degenerated areas, and longitudinal tenotomy may influence the local circulation in a beneficial way. It is still debatable why tendinopathic tendons respond to surgery. For example, we do not know whether surgery induces revascularization, denervation or both, resulting in pain reduction. It is also unclear how longitudinal tenotomy improves vascularization. As the biology of tendinopathy is being clarified, more effective management regimens may come to light, improving the success rate of both conservative and operative management. ■

Extracorporeal Shock Waves Influences Migration, Proliferation and Growth of Human Mesenchymal Stem Cells

The Effectiveness and Importance of Mechanotransduction within Differentiated Human Connective Tissue and Adult Stem Cells (in vitro study)



H. Neuland*,

Y. Delhase**,

H.-J. Duchstein***,

A. Schmidt**, **W. Bloch****

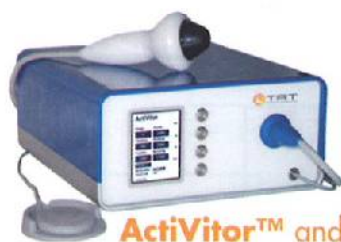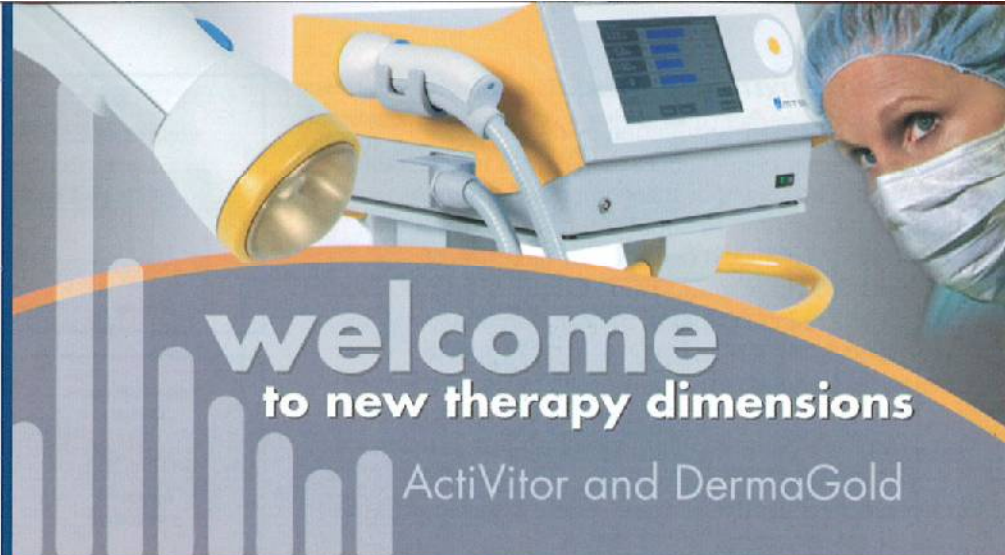
* ZES, Centre for Extracorporeal Shock Wave Therapy, Kronberg im Taunus

** Institute for Cell- and Molecularbiology, German Sports University Cologne

*** Pharmaceutical Insitute University Hamburg

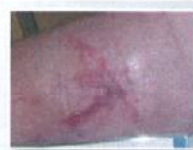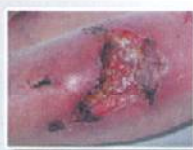Introduction

Previously the Extracorporeal Shock Wave Therapy (ESWT) was established for example for disintegrating renal calculi and gallstones. Currently the ESWT is successfully used in therapy against pseudoarthrosis, plantar fasciitis, tendinosis calcarea and wound healing disorders. Numerous in vivo studies underline the good results of this method of therapy. Our studies are focused on cellular effects of extracorporeal shock waves on migration, proliferation and growth of isolated human mesenchymal stem cells (MSCs). MSCs have been discussed for a very long time as being a useful tool for the treatment of various disfunctions. For therapeutic application of MSCs different invasive methods have been described before. Shock waves are generated extracorporeal and would represent a first non-invasive way to influence and guide MSCs to the target area.



ActiVitor™ and DermaGold™ offer:

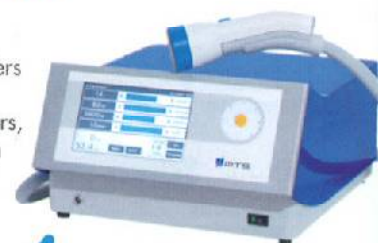- New therapy for skin lesions
- Comfortable hand held applicators, focused and soft-focused
- Electrohydraulic shock wave source with high efficacy
- Low operating costs
- Stimulates healing of musculoskeletal disorders and skin healing
- Exchangable applicators, always the right system for your specific need



Anesthesia-free

ActiVitor™ and DermaGold™ employ innovative applicators that emit unique soft focused shock waves over a broad surface. This significantly reduces the pain associated with shock wave treatment and eliminates the need for anesthesia for even better results.

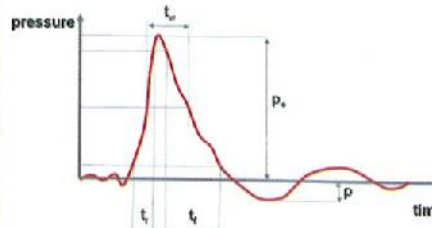
Two shock wave systems, one company, offering the full range of therapy options using shock waves. TRT Tissue Regeneration Technologies present DermaGold™ and ActiVitor™, unique therapy systems to specifically utilize the biological effects of shock waves, stimulating tissue regeneration. In cooperation with MTS Europe GmbH in Germany TRT expands the field of shock wave therapy to the treatment of skin lesions including traumatic wounds, burns, chronic wounds and venous ulcers.



USA • TRT Tissue Regeneration Technologies, LLC
www.trtik.com • Ph: +1 770 966 1315 • info@trtik.com

Europe • MTS Europe GmbH
www.mts-medical.com • Ph: +49 7531 36185 0 • info@mts-medical.com

Characteristics of the ESW



- High peak pressure (100 MPa)
- Short lifecycle (10 ms)
- Rapid pressure rise time (< 10 ns)
- Broad spectrum of frequencies (16 Hz – 20 Mhz)
- High shear stress at the interface



For our studies we use the piezoelectric extension of Piezason 100 (Wolf Inc. Knittlingen, Germany)

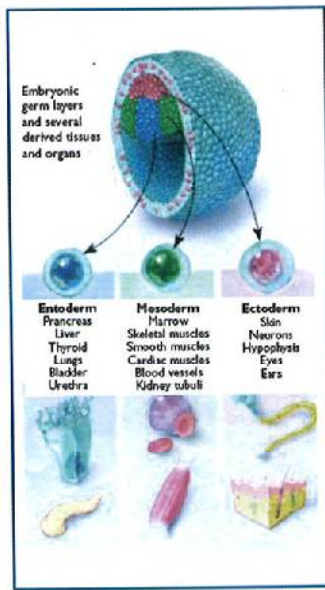
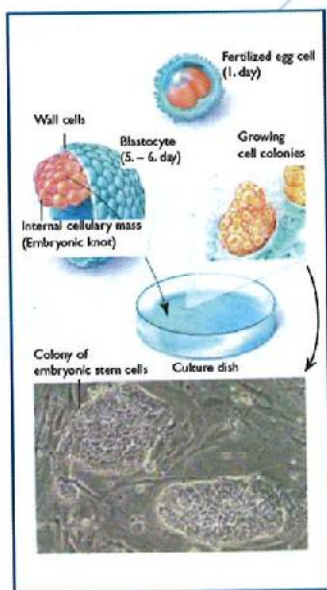
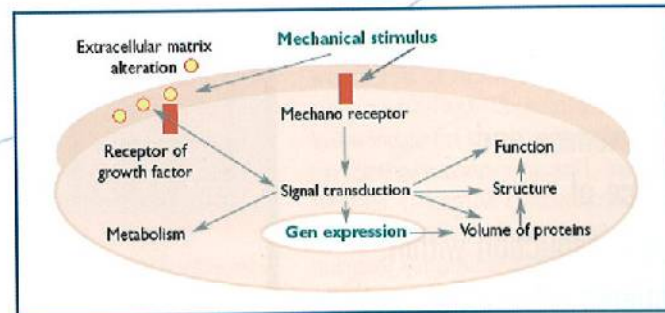
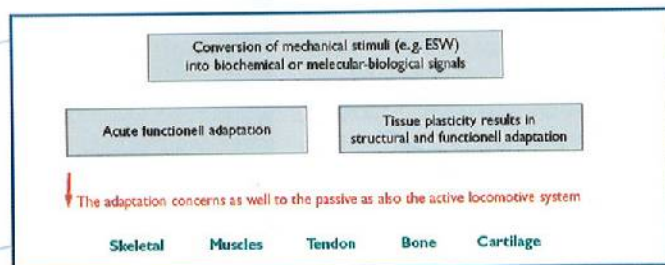
Mechanotransduction

The Mechano Transduction leads to the transformation of mechanical sensations into cellular impulses. The routes of these impulses are time-dependent in different supporting connective tissue. These routes induce a certain flow direction of information. There after arising follow-up signals, which are considered as biological information units, lead to very specific signals and thus to equally specific biological transformation within the cellular structure.

The adherence to precise method of application by means of mechanical stimulus is of utmost importance.

For the first time we were able to prove that mechanical activation of stem cells is possible with the help of extra corporal shock waves.

Hereby establishing further therapy methods.



Embryonic Stem Cells

Stem cells first appear during in the early embryonic development. The fertilized ovum (Zygote) already represents a totipotent stem cell, which is able to develop all kinds of human tissue.

Adult Stem Cells

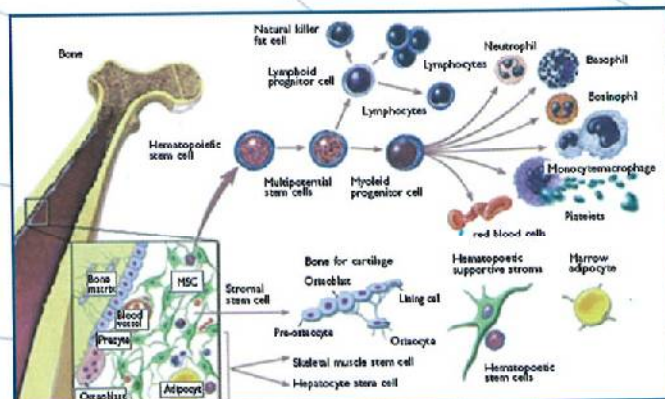
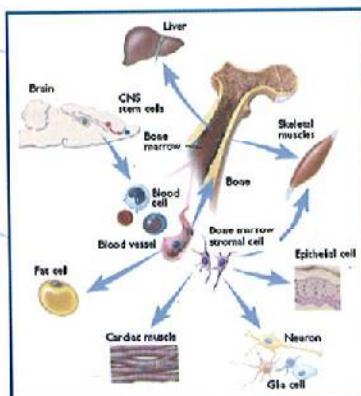
Within the grown-up body stem cells are found during the whole life. These so-called adult stem cells mainly occur in the bonemarrow, but also in the liver and brain. Until today it is not exactly clear as to whether they might exist in other organs as well.

As opposed to embryonic stem cells which can diversify into all types of tissue, adult or specific stem cells exhibit a limited potential for differentiation.

Adult or tissue specific stem cells differentiate into different types of tissue.

The bone marrow contains two types of stem cells:

the haematopoetic (HSC) and the mesenchymale (MSC) stem cells



Mesenchymal Stem Cells (MSCs)

The MSCs are omnipotent, they are able to differentiate not only in vivo but also ex vivo in special tissue cells: heart and skeleton muscle cells, bone and cartilage cells, connective and fat tissue.

Ways of Differentiation of MSCs

The purpose of the MSCs is the regeneration and repair of tissue.

This means:

Stem cells are necessary for the reparation and regeneration within living tissue.

Furthermore:

Aging is a process of imbalance between degeneration and regeneration.

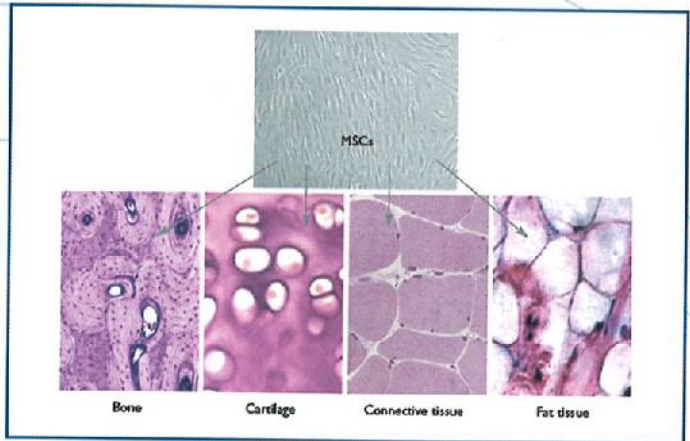
Putting it differently:

The loss of self-renewal in adult stem cells describes one of the most important reasons for growing old.

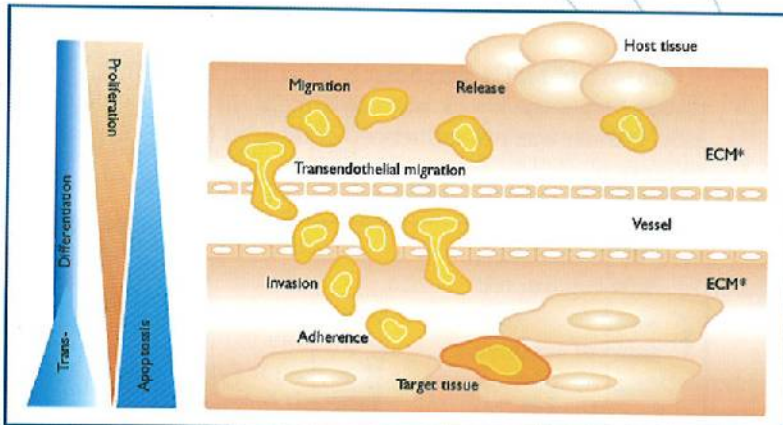
The question of the following study was:

Are extracorporeal shock waves able to influence the activity, proliferation and growth of MSCs?

The study was approved by the local ethics committee and conforms to the declaration of Helsinki.



Some pictures are to find by internet <http://stemcells.nih.gov/info>



The Influence of Extracorporeal Shock Waves on Migration Activity of Mesenchymal Stem Cells (MSCs)

* ECM: Extra Cellular Matrix

Cell Culture and Manipulation

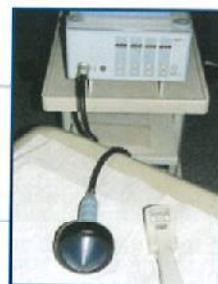
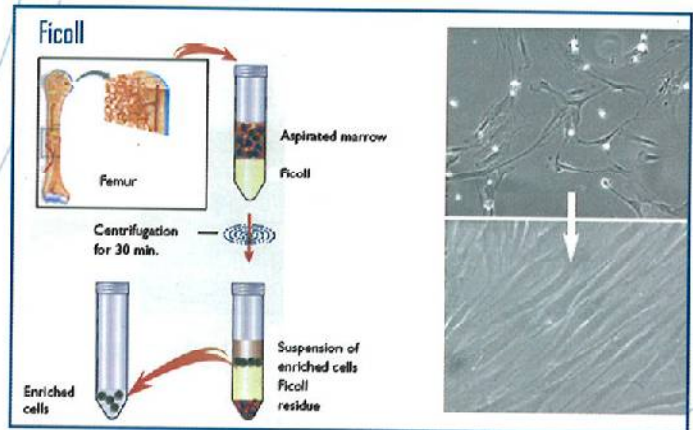
Purification and Selection of Marrow-Derived Stroma Cells

MSCs Cell Culture and Quality Control

Microscopic assessment of the morphology

- Flow cytometry
- CFU-Assay
- Differentiation assay

The differentiation potential of MSCs was controlled by culturing the cells under conditions that were favourable for adipogenic, osteogenic and chondrogenic differentiation.



Before migration was started, cells were treated with shock waves Piezason 100, Company Wolf, Germany.

Materials and Methods

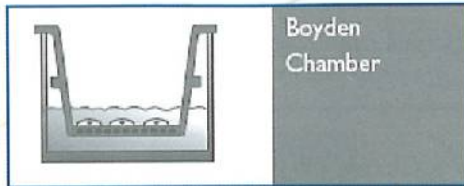
Application of Shock Waves

Shock waves were applied to adherent-MSCs. In order to imitate natural application in in vivo culture dishes were completely filled with media and covered with freshly prepared pork skin.

Ultrasound gel was placed on top of the pork skin to ensure best adjustment to the shock wave system.

Results

1. Boyden Chamber Assay



Boyden Chamber

Migration Assay was performed in a modified Boyden-Chamber assay. 5×10^4 single cells were put onto the top of a Falcon® HTS Fluoro Blok™ inserted and incubated for 8 hours in 20 % alpha-MEM.

For the shock wave treatment 3 parameters were altered:

- Number of applications (500 or 1000 applications)
- Frequency (2 or 4 applications per second)
- Density of energy (from 0,048 mJ/mm² to 0,238 mJ/mm²)

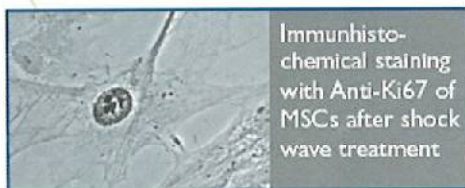
2. Growth rate



Confluent monolayer of MSCs

Equal amounts of freshly isolated MSCs were plated onto two culture dishes. After grown to a confluent monolayer one dish was treated with singular shock waves, the other untreated dish served as control. Afterwards MSCs were detached by Accutase™, counted and replated onto fresh dishes (5×10^4 cells/dish). The amount of MSCs was monitored until passage 5.

3. Proliferation Assay with Anti-Ki67



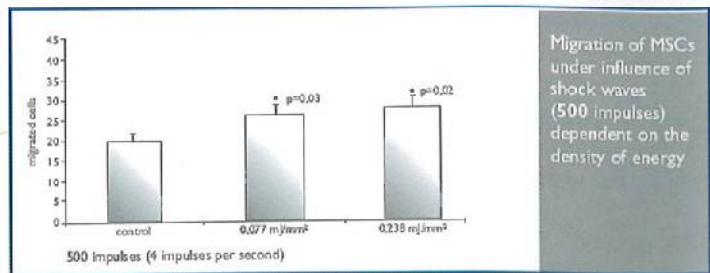
Immunohistochemical staining with Anti-Ki67 of MSCs after shock wave treatment

MSCs were fixed and used for immunohistochemistry by using rabbit anti-Ki67 (1:200, abcam, Cambridge, UK) to detect proliferative nuclei. Immunohistochemistry was developed by DAB. Positive and negative nuclei were microscopically quantified.

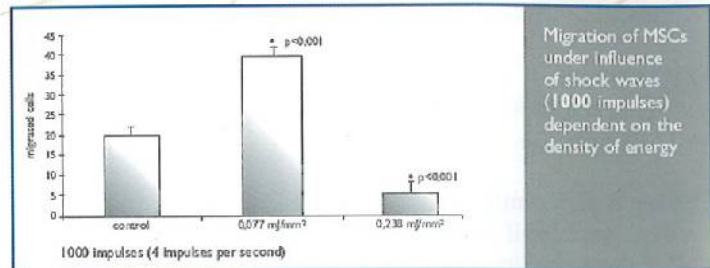
Summary and Conclusions

- Shock waves increase the migratory activity of MSCs when using distinct conditions.
- The results of shock wave treatment depend on number of applications, frequency and density of energy.
- Shock waves significantly increase MSC growth in the first passage after treatment.
- Shock waves significantly increase MSC proliferation.
- Shock waves might be the first approach to mobilise stem cells without invasion.
- The strong effects of shock waves onto MSCs indicate that these cells can be influenced by mechanic stimuli.

Shock waves significantly increase the migratory activity of MSCs.

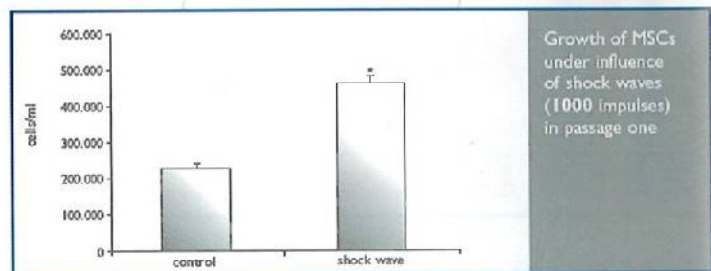


Migration of MSCs under influence of shock waves (500 impulses) dependent on the density of energy



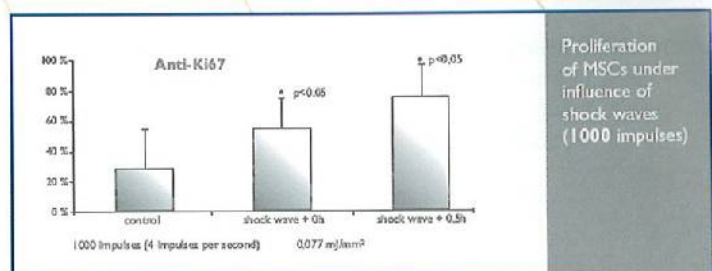
Migration of MSCs under influence of shock waves (1000 impulses) dependent on the density of energy

Growth of MSCs significantly increased in the first passage after the shock wave treatment. In later passages MSC growth was not influenced compared to the control reference.



Growth of MSCs under influence of shock waves (1000 impulses) in passage one

Shock waves significantly increase the proliferation of MSCs.



Proliferation of MSCs under influence of shock waves (1000 impulses)

In the case of more than 1000 impulses the activity of all tested parameters is reduced.

CONTACT:

ZES

Centre for Extracorporeal Shock Wave Therapy

Dr. Helmut Neuland

E-mail: dr.h.g.neuland@gmx.de

Westerbachstraße 23F

61476 Kronberg/Ts., Germany

Tel. +49 (0)61 73/94 05 80

Fax +49 (0)61 73/94 05 82

Improvement of Active Ankle Joint Dorsiflexion by the Use of Extracorporeal Pulse Activation Therapy (EPAT) in Patients with Chronic Achilles Tendinosis: A New Approach



Dr. med. Markus Gleitz

Médecin-Spécialiste en Orthopédie
[Orthopedic Surgery]
30, Grand Rue L-1660 Luxembourg
Tel.: (+352) 22 91 92 - Fax: (+352) 22 91 94
e-mail: marklux@mail.anonymizer.com

Summary

Calf muscle tightness and restricted dorsiflexion of the ankle joint are risk factors for many lower limb disorders, especially Achilles tendinosis. The origin of the muscle tightness remains unclear, but reducing the tension within the musculo-tendinous system leads generally to a reduction of pain.

The aim of this retrospective study was to investigate the possibility of improving active calf muscle extensibility by the use of Extracorporeal Pulse Activation Therapy (EPAT) in patients with chronic Achilles tendon pain and restricted dorsiflexion in the ankle joint. Therefore, pressure pulse waves were applied to the shortened calf muscles in 78 patients, and active dorsiflexion of the affected ankle joint was measured before and after therapy. The mean active dorsiflexion measured prior to Extracorporeal Pulse Activation Therapy was 3.6° (SD 3.7°; range -3° to 10°). After an average of 4.6 sessions with 6000 pressure waves per session, a significant increase in active dorsiflexion to 11.5° (SD 5.1°; range -2° to 21°) was found. Follow-up examinations conducted after an average of 4.2 months (range 3 to 6 months) after the end of therapy showed a persistent increase in maximal active dorsiflexion to 11.7° (SD 5.6°; range -2° to 22°). As the pain in the treated muscle indurations decreased, pulse intensity could be increased from 1.8 bar to 3.4 bar during therapy.

The mode of action of acoustic pulse waves in muscles is in accordance with the trigger point theory, but needs to be investigated in more detail by experimental studies.

Key Words:

EPAT, calf muscle shortening, stretching, muscle extensibility, Achilles tendinosis, trigger points.

Introduction

Shortened calf muscles are one of the main risk factors for recurrent Achilles tendinosis.^{1,3} The anamnestic information provided by patients reveals that many of them had been suffering from limited ankle joint dorsiflexion for years (e.g. heel up off the ground when in squat position). The cause of the muscle shortening remains unclear.

In most cases, stretching exercises are not sufficient to provide pain relief and to produce a lasting improvement in calf muscle extension.^{4,6} In contrast the use of heel lifts leads to a rapid decrease in pain, which demonstrates that the reduction of tension within the Achilles tendon is crucial in curing Achilles tendon pain.⁷

A possible cause of calf muscle shortening may be the presence of trigger points⁸ in the calf muscles. The permanent contracture of the actin-myosin filaments caused by trigger points, due to the energy crisis of the motor end-plate, leads to circumscribed muscle contractures which, in the presence of a sufficient number of trigger points, result in a measurable overall shortening of the affected muscles and in a limited dorsiflexion of the ankle joint. There are numerous causes for trigger point development, ranging from mechanical overstrain, trauma or poor posture to articular, neurogenic or remote muscular disorders (satellite trigger points). Rest and medicaments (NSAID) help in pain relief, but do not eliminate the underlying contracture, which persists for years and leads to recurrent injuries. With

time the trigger pathology often increases, as the malfunction induces a permanent overload of neighboring muscle areas.

One of the most effective therapies in use is the application of manually administered mechanical pressure on the trigger points.⁸ This is generally done by using the friction massage technique, followed by muscle stretching. Examinations into the effectiveness of classical trigger point therapy in improving active calf muscle extensibility are not dealt

within the citable literature. The effectiveness of calf muscle stretching alone is discussed controversially,^{4,6,9} as this therapy approach is considered to induce only a temporary and little improvement in flexibility.^{5,10}

In the last few years, the use of low to medium energy Extracorporeal Pulse Activation Therapy (EPAT) has become increasingly established in the treatment of myofascial pain, especially in the German speaking European countries (Germany, Austria, and Switzerland). On the basis of the aforementioned pressure application theory in the treatment of trigger points, the question is, whether acoustic pulse waves are able to provide an improvement in the extensibility of shortened calf muscles.

Material and Methods

Subjects

A retrospective study was conducted on 78 patients of an orthopedic practice (56 men and 22 women), mean age 45.3 years (SD 11.2; range 23 to 58 years), with unilateral chronic (> 6 months) Achilles tendon pain (mean 21.2 months; range 6 to 137 months). 69 patients complained about a mid-portion tendon pain, 9 about an insertional pain. All patients were recreational athletes and had a history of failed conservative treatments for Achilles tendon pain with NSAIDs, local cortisone injections, and physiotherapy. Physiotherapy included stretching exercises but they were not executed regularly and were not part of a specific stretching program. The inclusion criterion was a reduction in active ankle joint dorsiflexion equal or less than 10°, due to shortened calf muscles when examined at full hip and knee extension.

Device for Extracorporeal Pulse Activation Therapy (EPAT)

Therapy was carried out with the D-Actor® 100 system (Fig. 1) developed by Storz Medical AG* for orthopedic pain therapy in humans. The machine produces acoustic pulses with an energy flux density (EFD) up to 0.23 mJ/mm² and a maximal pulse frequency of 15 Hz.

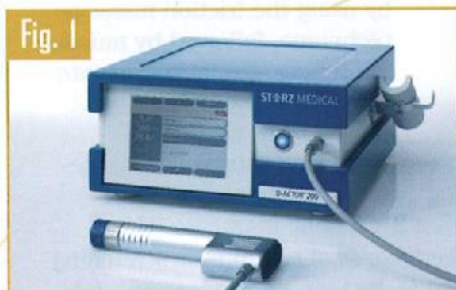

Fig. 1
D-Actor unit

The mode of action is identical to that used by pneumatic jack-hammers: a ballistic source (air compressor) generates stress waves by means of a projectile impacting a solid applicator in the handpiece (Fig. 2). The face of the applicator (20-mm diameter; Fig. 3) has to be covered with coupling gel and then fixed in tight contact with the skin. The pressure used to drive the projectile can be varied continuously from 1 bar to 4 bar using a dial on the front panel of the control unit (1 bar = 10⁵ Pa).

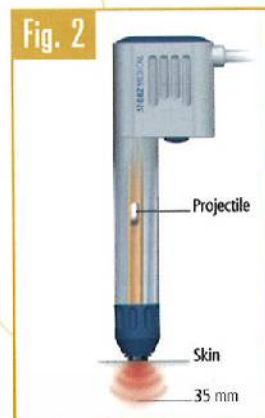


Fig. 2
Schematic view of D-Actor hand piece emitting radial pressure waves (no focus)



Fig. 3
20-mm D-Actor applicator of hand piece

The generated pulse of this type of device is a pressure wave and not a shock wave. It consists of a fast leading positive phase with a peak positive pressure as high as 5-8 MPa, followed by a negative phase. The -6 dB region of the pressure field is not a cigar-shaped focal volume, as typically found in extracorporeal shock wave therapy (SWT) derived from shock wave lithotripters, but rather a region of

space that extends radially from the applicator surface (maximum energy at the skin level), decreasing into the tissue with a penetration depth of 3-4 cm. The distance and the width of the -6 dB pressure field are consistent with the Rayleigh distance that bounds the near field of a piston source.¹¹

Procedure of Extracorporeal Pulse Activation Therapy (EPAT)

All patients underwent 4 to 6 Extracorporeal Pulse Activation Therapy (EPAT) sessions of the calf muscles at weekly intervals, in addition to receiving 4 local treatments with focused Extracorporeal Shock Waves (ESW) in the distal Achilles tendon (maximum 5 cm above the calcaneus). During each session, 6000 pressure pulse waves were applied to the calf muscles, with the patient lying in the prone position on the treatment table (Fig. 4). Pressure waves were mainly administered locally to the

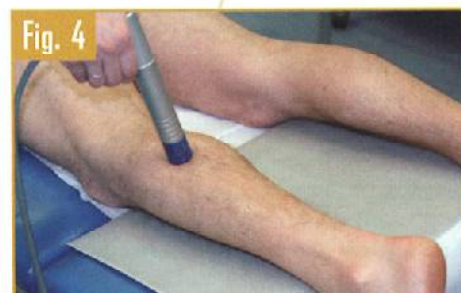

Fig. 4
Calf muscle treatment with pulse transmitter (D-Actor)

proximal gastrocnemius muscles, where most palpable indurations were found. The middle part of the soleus muscle was treated through the gastrocnemius muscles, whereas the distal muscle portion, often indurate as well, was freely accessible medial and lateral to the proximal Achilles tendon.

The palpable muscle indurations were considered as areas of trigger points and were therefore in the focus of the therapy. These areas were always more painful during the pressure wave treatment than the rest of the calf muscles. They were treated locally with 500-1000 pulses each, until the pain diminished. After choosing 4-6 trigger areas per session, the remaining 1500-2000 pulse waves were administered widely spread over the rest of the calf muscles (smoothing technique).

The maximum driving pressure as a measure for the pulse intensity was adjusted to the patient's pain threshold

and was tried to be increased during therapy. The pulse repetition frequency was 15 Hz. The number of sessions was determined according to the disappearance of pain during the treatment, with a maximum of 6 sessions. Application of pressure waves was strictly avoided over vessels and nerves. All therapies were executed by the same orthopedic physician (MG), who has an experience of several thousand pressure wave and shock wave treatments.

Instrumentation and Measurement of Ankle Joint Dorsiflexion

The active dorsiflexion of the ankle joints was measured by means of a BROM gravity goniometer** made of transparent plastic.

The examiner (MG) sat at the level of the ankle and held the goniometer against the patient's foot sole without exerting any pressure. Patients lay prone on a standard treatment table, both hip and knee joints extended. This is the position in which the gastrocnemius is maximally stretched. The foot was hanging over the table's edge with the hip in neutral rotation. Before measurement patients were asked to actively dorsiflex and plantar flex the ankle through the available ROM 4 times for the purpose of preconditioning the soft tissues, according to the procedure recommended by Zito et al.¹² After this preparation the next maximum active dorsiflexion angle was taken as the measurement. Measurements were taken before treatment, 1 week after the last treatment and as a follow-up 3 to 6 months later.

Instrumentation and Statistical evaluation

The statistical evaluation was performed using the SPSS*** software (version 11.5.0). The results of ankle mobility are expressed as mean with standard deviation (SD). Differences in active ankle joint dorsiflexion before and after treatment were calculated with a non-parametric test for paired samples using the Wilcoxon signed ranks test. A p-value less than 0.05 was considered significant.

Results

The mean active dorsiflexion measured prior to Extracorporeal Pulse Activation Therapy was 3.6° (SD 3.7°; range -3° to 10°). After an average of 4.6 sessions (range 4 to

* Storz Medical AG, 8274 Tägerwilen, Switzerland

** Performance Attainment Associates, P.O. Box 528, Lindstrom, MN 55045

*** SPSS Inc., Chicago, USA

6 sessions) a significant increase ($p=0.016$) in active dorsiflexion to 11.5° (SD 5.1° ; range -2° to 21°) was found. Follow-up examinations conducted after an average of 4.2 months (range 3 to 6 months) after the end of pressure wave therapy showed a significant increase ($p=0.013$) in maximal active dorsiflexion to 11.7° (SD 5.6° ; range -2° to 22°). No significant difference was identified between the results immediately after the end of therapy and at follow-up 4.2 months later ($p = 0.86$).

During therapy the pressure wave intensity could be increased in all patients. The average intensity at the first session was 1.8 bar (range 1.6 to 2.6 bar) and at the last session 3.4 bar (range 3.0 to 4.0 bar). Palpation after therapy showed a much softer muscle tissue and a disappearance of most indurations. Patients reported the feeling of more flexible calf muscles and an easier gait or running.

Side effects included small subcutaneous hematomas during the first two sessions. Sonographic examinations excluded any deeper-sited lesion in the muscles. Treatments could be continued at weekly intervals. Temporary muscle soreness for 1-3 days after the first two sessions was common. These symptoms were treated with paracetamol. None of the patients required early termination of the therapy.

Discussion

Extracorporeal Pulse Activation Therapy (EPAT) for treating muscle shortening is a new approach. The gain of ankle joint dorsiflexion after EPAT is more than 8° and lasts at least for 4 months. Consequently, this therapy seems to be superior to conventional stretching therapy, both in terms of the degree of improvement and in terms of the duration of its effectiveness. Radford et al¹⁰ reported in their literature review after meta-analyses from 5 trials a weighed mean difference (WMD) between 2° and 3° for the outcome of ankle dorsiflexion after static calf muscle stretches for up to 6 weeks. These results were obtained either immediately to maximal 72 hours after the end of a stretching therapy. Results weeks or months after stretching therapy are not reported.

Compared to the recommended daily stretching exercises, which need to be performed over a period of

several weeks, EPAT requires relatively little time as 4 to 6 therapy sessions are sufficient to achieve the described results. Because of the lasting improvement in calf muscle extensibility, EPAT seems a viable alternative to heel lifts in the treatment of chronic achillodynia since it allows the tension on the Achilles tendon to be reduced without running the risk of additional muscle shortening by heel elevation. Moreover, the treatment of a shortened muscle in overuse pathology of the related tendon represents a causal and more functional approach than the classic local Extracorporeal Shock Wave Therapy (ESWT) of the affected tendon alone.

The additional local treatment of the Achilles tendon with ESWT is, according to the existing literature and the author's knowledge, not known to have any influence on the calf muscle extensibility.

The mode of action of EPAT is in discussion. Even for the focused ESWT the mode of action is not fully understood and recent studies show that shock waves can have both, an analgesic effect¹³ and induce tissue repair.¹⁴ A plausible explanation for the effectiveness of EPAT might be given by the trigger point theory.⁸ The presence of trigger points in muscles causes a significant motor dysfunction with the clinical findings of a restriction of full stretch range of motion, a palpable increase in muscle tenseness and painful contraction knots.¹⁵ The histological findings in a contracture knot are segments of muscle fibers with extremely contracted sarcomeres.¹⁶ According to the energy crisis hypothesis¹⁷ an inadequate supply of ATP blocs the Ca^{++} pump and a sustained endogenous contracture develops as a beginning of a vicious cycle. In addition endogenous substances sensitize the muscle nociceptors and are responsible for the local tenderness of trigger points.

The following reasons for the effectiveness of the historically accepted combination of deep friction massage and stretching in the treatment of trigger points are discussed: disconnection of actin-myosin links within the contracted sarcomeres and improvement in local circulation along with the elimination of the ischemia-induced energy crisis.¹⁵

Extracorporeal Pulse Activation Therapy applies a similar principle: it brings mechanical energy into the

muscle. On the contrary to the classic manual techniques, EPAT uses much higher energy levels and is applied perpendicular to the longitudinal muscle fibers. Therefore it might be more efficient in interrupting local muscle contractures than the longitudinal stretching.

An argument for this theory is that indurations found in the calf muscles were very painful to EPAT during the first sessions and that they became soft and painless during therapy, together with the reported improvement of active ankle dorsiflexion.

Although the trigger point theory itself seems convincing, reduction of the treatment to the painful trigger points only is, in the opinion of the author, misleading and is not fully consistent with the practical experience of this study. In fact, the increase in ankle dorsiflexion achieved by an exclusively local treatment of the painful contracture knots within the muscle bellies of the gastrocnemius and soleus muscles remains far behind the improvement provided by the combined treatment of both individual spots and larger muscle areas described above (smoothing technique of the whole muscle). This would mean that the muscle shortening is not only due to the painful, active trigger points but also due to painless latent trigger point areas within the whole muscle, which also respond to EPAT.

Conclusion

The results of this practical study are encouraging, but need to be verified by means of methodically more valid studies and by conducting experimental examinations of the specific mode of action. Except for the pain perceived during treatment, EPAT has only minimal side effects and is indicated for almost all patients with calf muscle shortening.

References

1. Krivickas LS. Anatomical factors associated with overuse sports injuries. *Sports Med.* 1997 Aug 1997; 24(2):132-146.
2. Kaufman KR, Brodine SK, Shaffer RA, Johnson CW, Cullison TR. The effect of foot structure and range of motion on musculoskeletal overuse injuries. *Am J Sports Med.* 1999 Sep-Oct 1999; 27(5): 585-593.
3. McCrory JL, Martin DF, Lowery RB, et al. Etiologic factors associated with Achilles tendinitis in runners. *Med Sci Sports Exerc.* 1999 Oct 1999; 31(10):1374-1381.

4. Alfredson H, Lorentzon R. Chronic Achilles tendinosis: recommendations for treatment and prevention. Sports Med. 2000 Feb 2000; 29(2):135-146.
5. Harvey L, Herbert R, Crosbie J. Does stretching induce lasting increases in joint ROM? A systematic review. Physiother Res Int. 2002 2002; 7(1):1-13.
6. Youdas JW, Krause DA, Egan KS, Therneau TM, Laskowski ER. The effect of static stretching of the calf muscle-tendon unit on active ankle dorsiflexion range of motion. J Orthop Sports Phys Ther. 2003 Jul 2003; 33(7):408-417.
7. Davis WL Jr, Singerman R, Labropoulos PA, Victoroff B. Effect of ankle and knee position on tension in the Achilles tendon. Foot Ankle Int. 1999 Feb 1999; 20(2):126-131.
8. Travell JG, 1901-, Simons DG. Myofascial pain and dysfunction : the trigger point manual. Baltimore: Williams & Wilkins; 1983.

Table I. Results: Active Ankle Joint Dorsiflexion before and after EPAT

Ankle Dorsiflexion (Degrees)	Treatment Group (n=78)
Before therapy	3.6 +- 3.7
After therapy	11.5 +- 5.1
P	0.016 ^a
Follow-up	11.7 +- 5.6
P	0.013 ^b

^a Comparison between before and after therapy

^b Comparison between before therapy and at 4.2-month follow up

9. Porter D, Barrill E, Oneacre K, May BD. The effects of duration and frequency of Achilles tendon stretching on dorsiflexion and outcome in painful heel syndrome: a

randomized, blinded, control study. Foot Ankle Int. 2002 Jul 2002; 23(7):619-624.


10. Radford JA, Burns J, Buchbinder R, Landorf KB, Cook C. Does stretching increase ankle dorsiflexion range of motion? A systematic review. Br J Sports Med. 2006 Oct 2006; 40(10):870-5; discussion 875.
11. Cleveland RO, Chitnis PV, McClure SR. Acoustic field of a ballistic shock wave therapy device. Ultrasound Med Biol. 2007 Aug 2007; 33(8):1327-1335.
12. Zito M, Driver D, Parker C, Bohannon R. Lasting effects of one bout of two 15-second passive stretches on ankle dorsiflexion range of motion. J Orthop Sports Phys Ther. 1997 Oct 1997; 26(4):214-221.
13. Ohtori S, Inoue G, Mannoji C, et al. Shock wave application to rat skin induces degeneration and reinnervation of sensory nerve fibres. Neurosci Lett. 2001 Nov 23 2001; 315(1-2):57-60.
14. Wang CJ, Wang FS, Yang KD, et al. Shock wave therapy induces neovascularization at the tendon-bone junction. A study in rabbits. J Orthop Res. 2003 Nov 2003; 21(6):984-989.
15. Mense S, Simons DG. Muscle pain : understanding its nature, diagnosis, and treatment. Philadelphia: Lippincott Williams & Wilkins; 2001.
16. Simons DG, Stolov WC. Microscopic features and transient contraction of palpable bands in canine muscle. Am J Phys Med. 1976 Apr 1976; 55(2):65-88.
17. Simons DG, Travell J. Myofascial trigger points, a possible explanation. Pain. 1981 Feb 1981; 10(1):106-109.

SWISS DOLORCLAST[®] CLASSIC

THE NEXT GENERATION → FDA - APPROVED

- 20 Hz MAXIMUM TREATMENT FREQUENCY
- 0,55 mJ/mm² MAXIMUM ENERGY FLOW DENSITY
- GEL BOTTLE AND CABLE HOLDER INCLUDED
- FOOT- AND HANDPIECE CONTROLLED APPLICATION
- STANDARD- AND POWER+ HANDPIECE INCLUDED
- SIX APPLICATORS
FOR BEST TREATMENT ADAPTATION
RADIAL 6 mm, 10 mm, 15 mm
FOCUS 15 mm
TRIGGER 15 mm
PLANAR 36 mm

- INCLUSIVE:
TRIGGER APPLICATION - DVD
SCIENTIFIC INFORMATION UPDATE - CD
COMPREHENSIVE ACCESSORIES



EMS S.A.
Ch. de la Vuarpillière 31
CH-1260 Nyon
Switzerland

Tel. +41 22 99 42 607
Fax +41 22 99 44 701
welcome@ems-ch.com
www.ems-medical.com

EMS⁺
ELECTRO MEDICAL SYSTEMS