

Effective Shock Wave Therapy

Implementing ESWT in the treatment of the iliotibial band friction syndrome (ITBFS)

Prof Dr Matthias Beck, Institute of Clinical Anatomy, AVT College of Osteopathic Medicine GmbH & Co. KG, Germany

The iliotibial band friction syndrome or ITBFS develops in the lateral aspect of the knee joint between the lateral epicondyle of the femur and the iliotibial tract as a result of excessive mechanical stress. It manifests itself as a locally well-defined irritation of the tissue in this area. In most cases, repetitive bending and stretching of the knee joint are the main causes for this medical condition.

The complaint very frequently affects runners (runner's knee) and cyclists, but also soccer and basketball players, rowers and other athletes. In the German speaking area there are no valid data on the incidence of ITBFS. In the USA, the incidence of all knee joint complaints resulting from excessive stress is stated as 1.6 to 12% with the highest frequency of 15 - 24% observed in cycling.

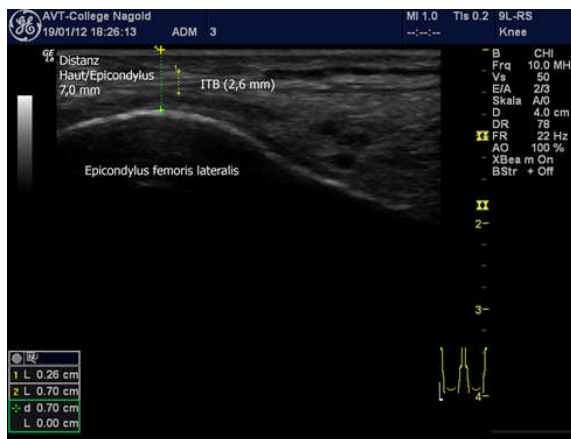
Diagnosis of ITBFS

After exclusion of a lateral meniscopathy, an injury of the lateral collateral ligament and a patellofemoral pain syndrome by means of differential diagnosis, a diagnosis of ITBFS can usually be established clinically at first.

Evidence is provided by pain in the lateral aspect of the knee joint, slightly proximally to the lateral intra-articular space, resulting from excessive stress to be determined in the course of the anamnesis, as well as by a local pain on palpitation above the lateral epicondyle of the femur under a flexion angle of the knee joint of approximately 30°. (Complementary manual examinations can be found in the online version of this article). In many ITBFS cases, the sonographic examination of the knee joint shows a thickening of the ITB (from 1.1 ± 0.2 mm to 5.4 ± 2.1 mm on average) in the lateral longitudinal section above the lateral epicondyle of the femur, and an accumulation of liquid as an expression

of an inflammatory infiltration of the fatty tissue between the ITB and the lateral aspect of the femur and the knee joint or the inflammation of a secondarily developed bursa in this area.

An additional examination of the patient using magnetic resonance imaging should be considered in those cases in which the conservative treatment has not resulted in an elimination of the complaints and a recovery of the functional capacity of the knee joint. In case of an ITBFS, the MRI makes it possible to represent the typical compartment-related signal changes in the T1 and T2 weighted images or to identify other medical conditions of the knee joint by means of differential diagnosis.



Sonographic examination of ITB

Treatment strategies

At first, ITBFS treatment should always be conservative (table). In the course of the treatment it is indispensable to reduce the stress and often also the athletic activity of the affected person by at least 50% of the original level (or to reduce training to a stress level that does not cause pain). Supervision of training and stress conditions is a very important aspect of the therapy as they may have to be corrected or optimised depending on the type of sport. Regardless of the sport that has caused the excessive stress, patient specific factors such as leg length differences, leg axis deviation, foot overpronation, and myofascial imbalances need to be corrected. In a randomized and controlled study, the use of NSAIDs in the first 14 days of the treatment with due consideration of contraindications and, if necessary, local infiltration (1 ml lidocaine 1% with 1 ml methylprednisolone) could bring about a statistically significant improvement of the symptoms.

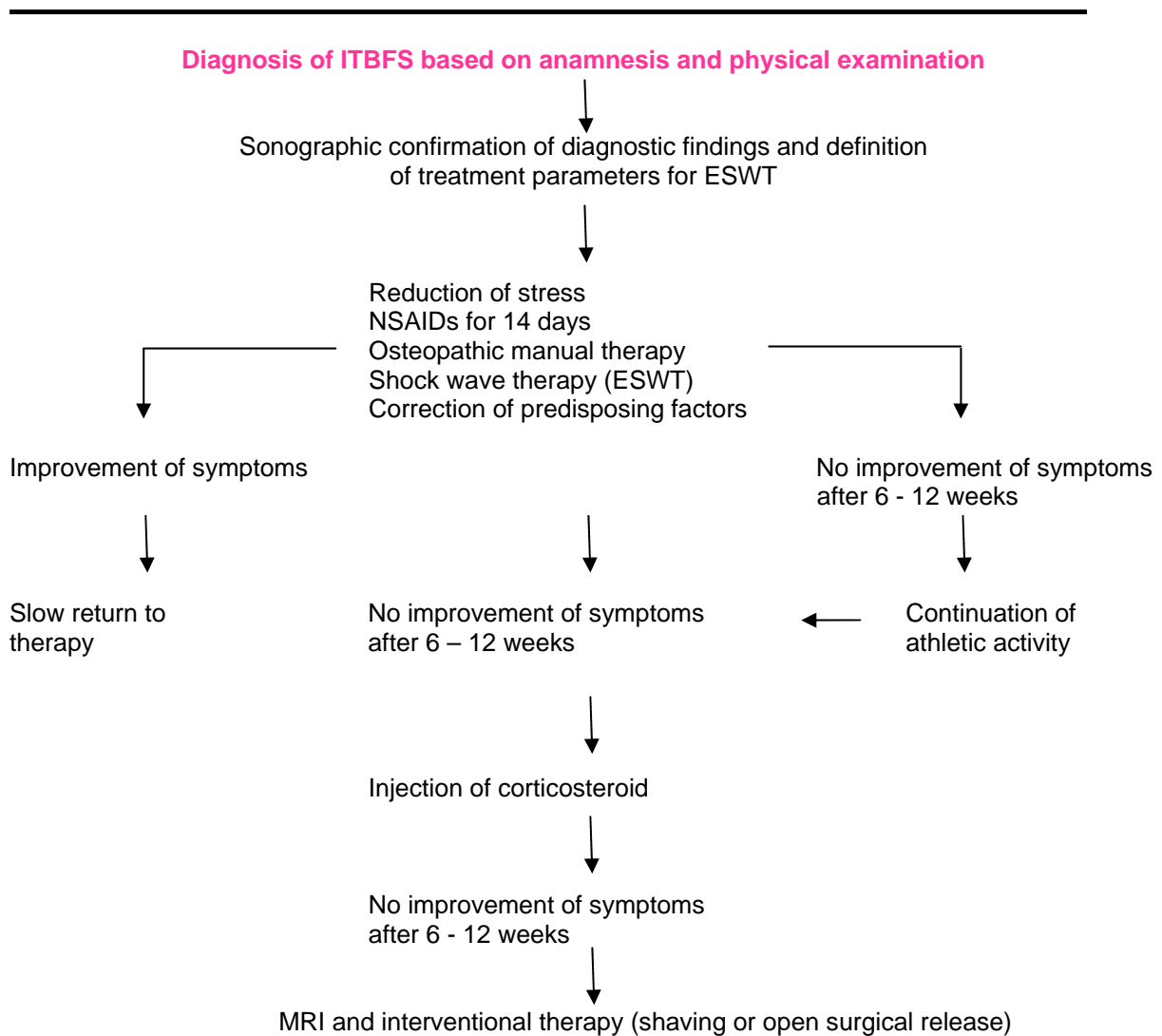
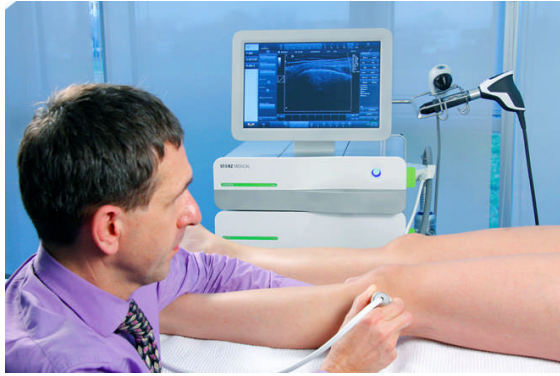


Table: Flowchart of ITBFS diagnosis and treatment

Conservative treatment with OMT and ESWT

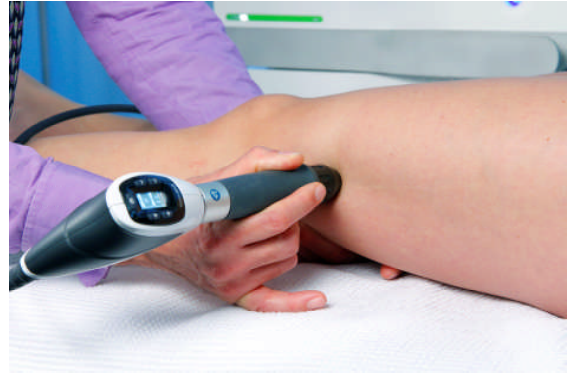The application of OMT (osteopathic manual therapy) is appropriate for those patients who have developed functional deficits of joint mobility and myofascial imbalances. In these cases, dysfunctions of the sacroiliac joints, the superior tibiofibular articulation and the tarsal joints are considered as *key points* of the therapy. In addition to muscle energy and positional release techniques, spray and stretch

techniques can be used for the treatment of muscle trigger points. They accelerate the reduction of pain as well as the return to the patients' training routine. The use of the extracorporeal shock wave therapy (ESWT) for treating ITBFS patients makes it possible to optimise the duration and result of conservative therapy strategies. Our experience has shown that the application of focused ESWT combined with radial shock or pressure waves is particularly effective.



Sonographic diagnostics with integrated ultrasound imaging, DUOLITH SD1 »ultra« (Photo © STORZ MEDICAL)

After defining the treatment area and depth by means of sonography, the focused shock wave is at first applied above the lateral epicondyle of the femur using an appropriate distance piece. Dosage is based on current and patient oriented tolerance limits and amounts to an energy flux density ranging from $0.1 - 0.3 \text{ mJ/mm}^2$ and approximately 2000 pulses at 4 - 5 Hz. If the sonographic image indicates the existence of a secondarily developed bursa and its inflammatory alteration between the ITB and the lateral epicondyle of the femur, dosage for the first treatment should tentatively be on a low energy level. This measure is followed by the treatment of the whole ITB and, depending on the actual diagnostic findings, of the vastus medialis and the anterior tibial muscle (anterolateral musculotendinous chain) with radial shock or pressure waves.



Radial shock wave treatment above the ITB (Photo © STORZ MEDICAL)

Above the ITB, the D35-S transmitter (35 mm) and, above the anterior tibial muscle, the D20-S transmitter (20 mm), are used for this treatment at 1.4 to 3.6 bar and 10 - 12 Hz. Finally, the mobility of the crural fascia and the fascia lata can be treated additionally with the handpiece at 2 - 4 bar. The pressure above the lateral epicondyle of the femur must be adjusted to a level that allows painless application. This measure enhances the resorption of the exsudative inflammatory infiltrate in the compartment between the medial surface of the ITB and the lateral epicondyle of the femur and needs to be verified by sonographic control. If conservative therapy delivers an insufficient result or even fails, interventional release methods of the ITB can be applied. Fenestration above the lateral epicondyle of the femur or z-shaped elongation can contribute to relieving the soft tissue structures and thus take away the pain and increase the tolerance for stress caused by athletic activities.

Conclusion

In most cases, conservative treatment of ITBFS is an effective therapy provided that it considers the temporary reduction of stress as well as the analytically founded exclusion of predisposing factors. The integration of an extracorporeal shock or pressure wave treatment into the therapy of ITBFS as a supplement to the known therapeutic regimen is based on positive experience. It can be used to optimise the duration and the result of the therapy, as our experience has shown. However, randomised and controlled studies of the application of ESWT for the treatment of ITBFS are not yet available.

//org@avt-osteopathie.de

**Please find the complete article together with an extensive literature list at:
www.medicalsportsnetwork.de (in German)**

Conflict of interests:

The author of this article holds seminars on the application of the extracorporeal shock wave therapy at the AVT College of Osteopathic Medicine in Nagold with the technical support of the companies KRÖNER Medizintechnik and STORZ MEDICAL. There is no financial compensation or support involved.

Source: English translation of the article »Zielführende Stoßwellentherapie - Implementierung des Tractus-iliotibialis-Friktionssyndroms (ITBFS)«, in: medicalsportsnetwork 02-2012