

Clinical Observations of Unusual Total Regeneration of a Left Metacarpal Paw Pad of a Female Chow Chow Dog

Erling Pedersen, D.C.

WOUNDS 2011;23(7):E16–E20

*From the Nordic Health Clinics,
Phuket, Thailand*

Address correspondence to:

Erling Pedersen, D.C.

Nordic Health Clinics

Tamarind Villas

76/89 Soi Suksan 1

Rawai 83130

Phuket

Thailand

Email: erlingip@hotmail.com

Abstract: A Chow Chow dog had completely chewed off her left metacarpal paw pad after a surgical removal of a piece of glass 4 years prior to the first appointment. The wound had remained open and non-healing during this time. Various standard medical procedures to heal the wound had failed. After living with this open wound for 4 years, the dog's owner consulted our clinic to treat the wound using extracorporeal shockwave therapy (ESWT). After three preliminary and two follow up ESWT sessions the wound was closed and the metacarpal pad was fully regenerated.

Four years prior to the first appointment at our extracorporeal shockwave therapy clinic under Nordic-Health Clinics in Spain, the Chow Chow had injured her left metacarpal paw pad by stepping on a piece of glass which penetrated and lodged deep into the pad. The glass remained unnoticed for a while but it was later removed with a subsequent inflammation and swelling of the pad. The inflammatory swelling became unmanageable and the veterinarian decided to administer multiple drainage punctures into the wound in a circle around the pad perimeter to drain the pus and the pad was bandaged. Over time, the dog pulled off the bandages and subsequently licked the wound continuously. This was not prevented by means of a physical obstruction, such as an Elizabethan collar. Eventually the dog managed to chew off the entire paw pad. Thereafter, the bandage was changed twice a day due to leakage of blood, pus, and extracellular fluid. Later the biting had mostly subsided but occasionally mild bleeding was observed. The wound did not show any signs of healing during this long period of time.

Over the next 3 years veterinarians made multiple attempts to control the wound by various standard medical means, hoping healing would take place. Failing in getting the wound to heal, alternative treatment options were suggested by veterinarians and included: euthanizing the dog, amputation of the foot at the proximal joint, and a skin graft, even though a positive result of this option was slim to none. The owners decided against all these options and continued to administer conservative wound care by using ointments and changing bandages once or twice a day.

In March of 2009 the dog's owners visited our clinic seeking extracorporeal

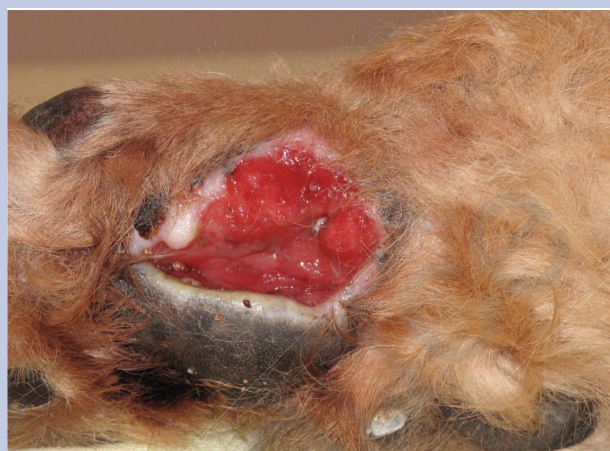
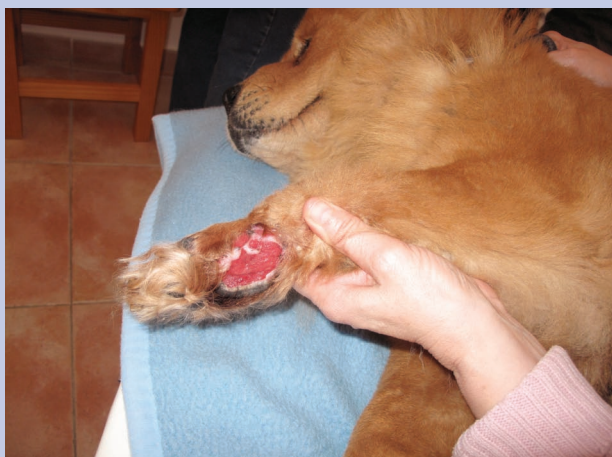
Figure 1. The dog presented with a 4-year-old, non-healing wound.

real shockwave therapy (ESWT) as a “last resort” (Figure 1). Our goal was to attempt to restore the integrity of the blood vascular system in the metacarpal pad and leg using standard ESWT for wounds.

The anatomy of canine paw pad is characterized by thin, pigmented, keratinized, hairless epidermis covering subcutaneous, collagenous, and adipose tissue that comprise the pads. These pads act as a cushion for the load-bearing limbs of the animal. The paw consists of the large, heart-shaped metacarpal pad (forelimb) or metatarsal pad (rear limb), and generally four load-bearing digital pads. A carpal pad is also found on the forelimb, which is used for additional traction when stopping or descending a slope (particularly in digitigrade species). Additional dewclaws were also present.

Examination of the wound and palpation of the muscles of the lower limb:

- the musculature of the mid portion of the limb was hard
- the wound was soft to the touch
- there was a rim of gray keratinized epidermis and white collagenous tissue
- the wound was deep red in color and moist.

The exposed musculature had minimal leakage of interstitial fluid. Minimal blood was produced during examination.

Methods

The objective of the treatment protocol was to use focused shockwaves in order to:

- Eliminate any restriction to the arterial and venous blood flow feeding the pad caused by a chronic

spasm of the muscle fibers and muscle bundles of the lower limb. This resembles the wound treatment protocol we normally follow in humans.

- Stimulate the progenitor cells^{1,2} of the visible gray keratinized epidermis and white collagenous tissue that would cause these cells to proliferate and prompting healing of the edges of the wound. Scab formation was expected.
- Open the capillary vessels of the muscle fibers resulting in a better blood flow and possibly neovascularization. This would make it possible for a natural metabolic function of the wound cells to occur.
- Stimulate the release of growth factors like VEGF, TGF- β , and anti-inflammatory effect due to nitric oxide (NO).¹⁻⁵

For the shockwave therapy, the STORZ MEDICAL Duolith SD 1 shockwave unit was used with the F-SW head and the long stand-off (1.5-cm focal depth). The wound was covered with sterile ultrasound gel on top of which a layer of transparent polymer plastic was placed. On top of the plastic a generous amount of regular ultrasound gel was deposited (Figure 2). The sound head was used at a 60-degree angle with ample gel in front of the sound head to accommodate complete connection through the gel of the acoustical wave into the outer layers so that there would be no air pockets between the sound head and the wound surface. The entry angle and penetration depth of the waves were precise to ensure that the lengthwise and crosswise directions of the waves would hit the muscle fibers. The waves would also hit the blood vessels and nerves. This application method

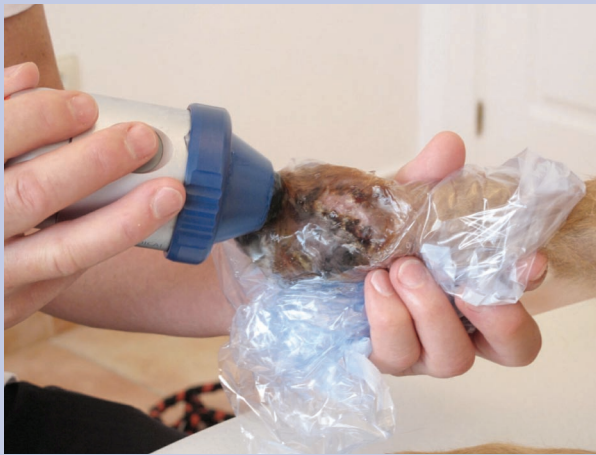

Figure 2. Treatment procedure. The wound was covered with sterile ultrasound gel, a layer of transparent polymer plastic, and ultrasound gel for coupling to the hand piece.

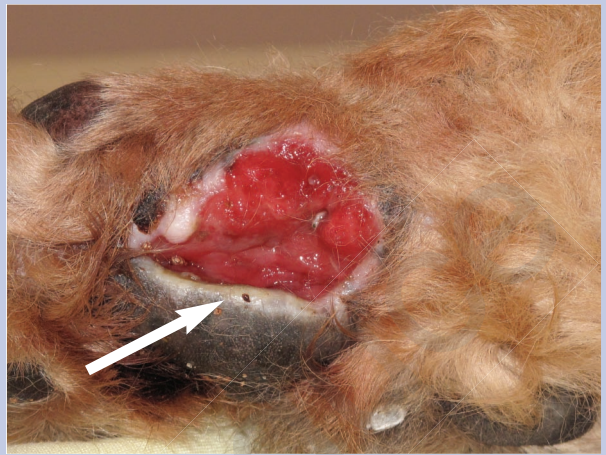


Figure 3. Before the third treatment new pad tissue was growing from the perimeter (white arrow).

is essential for proper blood flow through the structures. Waves were never intentionally pointed directly on the periosteum, but using the flat angles to gently bounce the waves off the bones, caused little or no discomfort, while maximizing the utilization of the energies.

Results

First treatment (March 1, 2009). The perimeter of the wound was exposed to the shock waves from the center of the wound towards the perimeter, gradually hitting all of the tissue as the treatment head was moved approximately 2 mm per shot in a circular fashion. Then a generous amount of gel was used on the posterior side of the lower limb proximal to the wound. The settings for each area were $0.20\text{mJ}/\text{mm}^2$ at 2.5Hz with a total energy of 1.962 Joules (300 pulses) deposited in the tissues.

Second treatment (March 15, 2009). The wound had started to bleed mildly shortly after the first treatment, which had not been seen for more than a year. The bleeding continued for about 2 days, after which it subsided and the color of the wound had now changed to a lighter red color. There were two or three spots of about 3mm^2 where slight bleeding was seen during the second visit. The muscles of the lower limb palpated soft much like the right lower leg did.

The same procedures as for the first treatment were followed in preparing and protecting the wound for the treatment. The middle of the wound was treated so that the entire surface and perimeter was covered. $0.20\text{mJ}/\text{mm}^2$ at 2.5Hz with a total energy of 2.616 Joules

(400 shocks) were deposited. The lower leg muscles were not treated during the second procedure.

Third treatment (April 18, 2009). The wound had not bled after the second treatment and the oozing of interstitial fluid had subsided, but the texture of the wound was still moist and had changed to a healthy pink color. Additionally, it was noted that new pad tissue was growing from one side (Figure 3).

Additionally to the standard procedure, the middle of the wound was treated, ensuring that the entire surface and perimeter was treated. $0.20\text{mJ}/\text{mm}^2$ at 2Hz with a total energy of 2.616 Joules (400 shocks) were deposited.

Fourth treatment (May 3, 2009). The pad tissue had kept growing, especially at the edge where growth was first seen. Now about 30% of the wound had healed over with the characteristic keratinized, hairless epidermis, collagenous, and adipose tissue. The focus was on this growing tissue while the open part of the wound was healing with patches of white cells. These cells have been interpreted to be mature, growing, collagenous cell patches. No histological samples were taken, as the proper equipment necessary to secure and protect such samples was lacking. Fourth treatment: $0.25\text{mJ}/\text{mm}^2$ at 2Hz with a total energy of 3.27 Joules (400 shocks) were deposited.

Fifth treatment (June 8, 2009). The pad has grown to cover about 70% of the original wound. The pad tissue was soft and felt like that of a puppy. The white edge of the pad that had shown a special activity from the start appeared to have been the precursor for the formation of

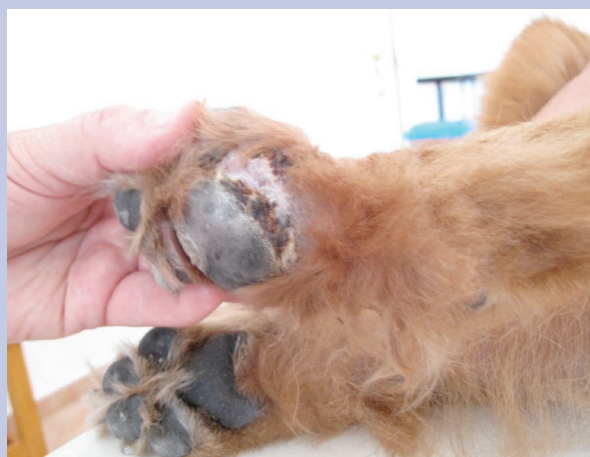

Figure 4. Final result prior to the scab falling off. The entire pad was completely healed, was harder to the touch, and was similar in appearance to the pad on the right leg.

the full body of the pad including the dark/grey outer keratinized epidermis. Treatment was again focused on the perimeter of the growing epidermis and on the few remaining patches of white cell conglomerates in the middle of the remaining red, moist part of the wound. The settings and energy used were: 0.30 mJ/mm² at 2 Hz with a total energy of 1.51 Joules (154 shocks) deposited.

Sixth treatment (June 14, 2009). The wound was now closed and protected against bacterial and other contamination. The owners had not needed to bandage the wound for the first time in 4 years. What was previously a raw red, bleeding, open portion wound was now replaced in part by crusty scar tissue and in part by pink solid collagenous tissue. The dog now walked without a limp and showed no interest in licking the former wound at all. It was decided to discontinue the treatment of the pad and the crusty edge.

Follow up (July 23, 2009). The entire pad was complete. It was getting harder to the touch and appeared much like the pad on the right leg (Figure 4). However, one curious thing was noted on the pad—there was one circular keratinized formation on part of the pad that was not seen on the right pad. The owners did not remember if the pad had this feature before it was chewed off. Also, the pad seemed somewhat larger than the right one.

Discussion

The reformation of the paw pad was a major step for ESWT science and warrants further studies into the

effects of shock waves on progenitor cells in tissues. This may be the first time a paw pad has regenerated completely, at least by ESWT as the treatment modality. Scientific work has already been done in this field as indicated in the below references. The healing of non-healing wounds using shockwaves is not new. Many types of wounds have been treated successfully by shockwaves which prompts due consideration by the scientific community as well as by all hospitals and other medical establishments that treat wounds. Conventional medical treatment protocols have proven inadequate and new measures must be urgently considered. Proper scientific trials must be conducted on all non-healing wounds that do not respond to standard medical treatments. The authors are ready, willing, and able to participate in such research, should there be an interest from the scientific community to explore this promising new treatment modality.

From the very start the dog cooperated fully before and during the procedure. It was contemplated that it would have been necessary to use restraints and a mouth guard on the dog as the dog had been very aggressive towards the veterinarian doctors. At our clinic the dog was calm but occasionally reacted slightly to the shockwaves, most likely when the waves hit the periosteum on perpendicular angles. She was, however, always at ease with the treatments and was always very eager to get into the clinic as she pulled her owner along heading through the clinic door straight for the treatment room.

Conclusion

These facts are interesting and may imply that shock waves when induced with care, precision, and purpose create no serious pain in soft tissues and the dog might even have felt good about the sessions, and wanting more for her own reasons. Why she accepted ESWT so easily remains a mystery. Whatever the inner psychological mechanism of a dog may be, the author will abstain from speculation and leave that to the experts in the field of dog psychology.

Acknowledgement

A news article based on this case report was previously published in the monthly magazine *Solkysten*.⁶

References

1. Berger M, Frairia R, Piacibell W, et al. Feasibility of cord blood stem cell manipulation with high-energy shock waves: an in vitro and in vivo study. *Exp Hematol*.

- 2005;33(11):1371–1387.
2. Dowthwaite GP, Bishop JC, Redman SN, et al. The surface of articular cartilage contains a progenitor cell population. *J Cell Sci.* 2004;117:889–897.
 3. Bischofberger AS, Ringer SK, Geyer H, Imboden I, Ueltschi G, Lischer CJ. Histomorphologic evaluation of extracorporeal shock wave therapy of the fourth metatarsal bone and the origin of the suspensory ligament in horses without lameness. *Am J Vet Res.* 2006;67(4):4:577–582.
 4. McClure SR, Sonea IM, Evans RB, Yaeger MJ. Evaluation of analgesia resulting from extracorporeal shock wave therapy and radial pressure wave therapy in the limbs of horses and sheep. *Am J Vet Res.* 2005;66(10):1702–1708.
 5. Ringer SK, Lischer CJ, Ueltschi G. Assessment of scintigraphic and thermographic changes after focused extracorporeal shock wave therapy on the origin of the suspensory ligament and the fourth metatarsal bone in horses without lameness. *Am J Vet Res.* 2005;66(10):1836–1842.
 6. Pedersen E. Nebbie fik trødepuden tilbage. *Solkysten.* 2010 May;74. Available at: http://solkysten.eu.dedi1613.your-server.de/upload/solkysten/Blad_maj2010.pdf. [Article in Danish].